Ultrasound in male infertility and MAGI

Francesco Lotti, MD, PhD

Assistant Professor of Endocrinology
Sexual Medicine and Andrology Unit
(Director Prof. Mario Maggi)

Department of Experimental and Clinical Biomedical Sciences

University of Florence, Italy

European Academy of Andrology

Athens, March 17, 2017

francesco.lotti@unifi.it

Role of male genital tract (MGT) color-Doppler ultrasound (CDUS)

Human Reproduction Update, Vol.21, No.1 pp. 56–83, 2015
Advanced Access publication on July 19, 2014 doi:10.1093/humupd/dmu042

human reproduction update

Ultrasound of the male genital tract in relation to male reproductive health

Francesco Lotti and Mario Maggi*

Sexual Medicine and Andrology Unit, Department of Experimental and Clinical Biomedical Sciences, University of Florence, Florence, Italy

- Infertility
- Malignancy
- Male accessory gland infection / inflammation

Role of male genital tract (MGT) color-Doppler ultrasound (CDUS)

1.Male infertility

CDUS clinical utility and impact on male reproductive health management

- Transrectal ultrasound
- Scrotal ultrasound

Human Reproduction Update, Vol.21, No.1 pp. 56–83, 2015
Advanced Access publication on July 19, 2014 doi:10.1093/humupd/dmu042

human reproduction update

Ultrasound of the male genital tract in relation to male reproductive health

Francesco Lotti and Mario Maggi*

Sexual Medicine and Andrology Unit, Department of Experimental and Clinical Biomedical Sciences, University of Florence, Florence, Italy

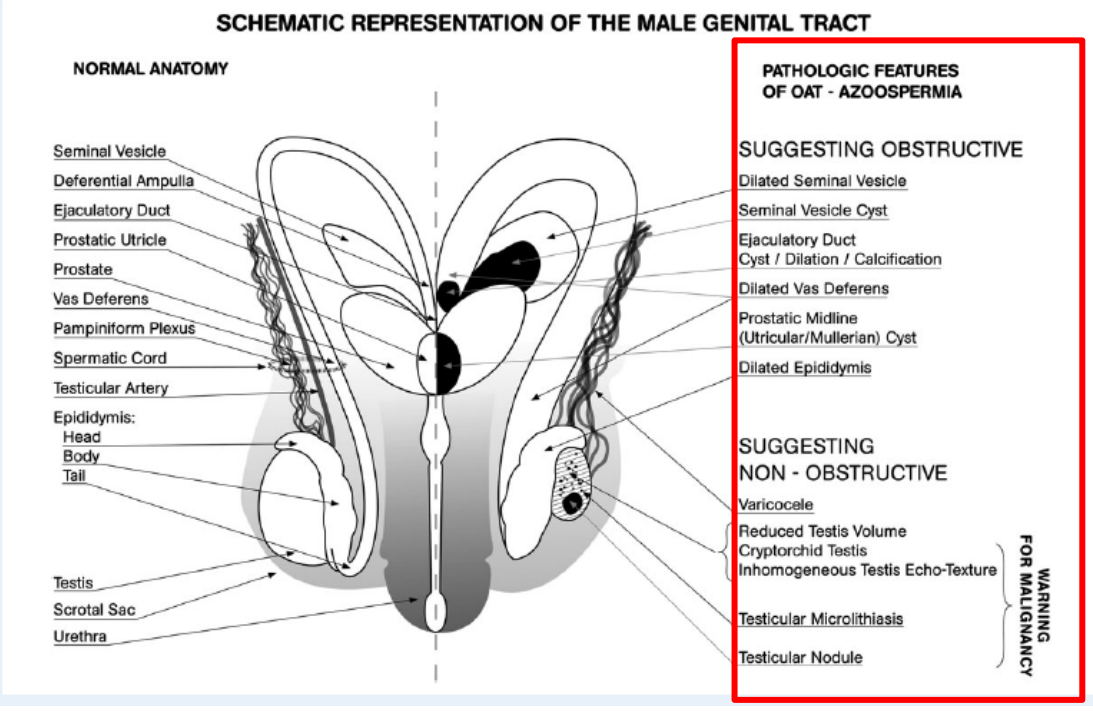

➢ Transrectal ultrasound

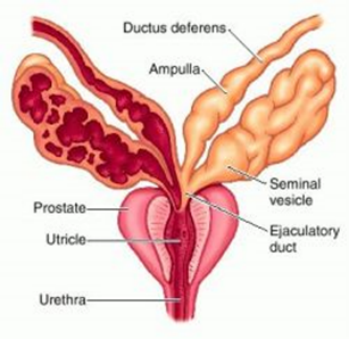

Clinical utility:

High:

a.Assessment of obstructive azoospermia/severe oligozoospermia

Moderate:

b.Assessment of prostate-vesicular inflammation

Low:

c.Information on hypogonadism

Human Reproduction Update, Vol.21, No.1 pp. 56–83, 2015
Advanced Access publication on July 19, 2014 doi:10.1093/humupd/dmu042
human reproduction update

Ultrasound of the male genital tract in relation to male reproductive health

Francesco Lotti and Mario Maggi*
Sexual Medicine and Andrology Unit, Department of Experimental and Clinical Biomedical Sciences, University of Florence, Florence, Italy

Transrectal ultrasound

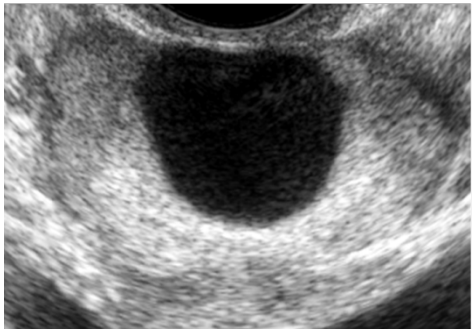

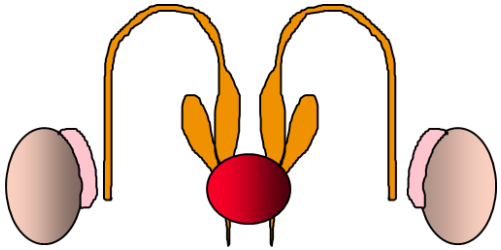

Clinical utility:

High:
a.Assessment of **obstructive azoospermia**/severe oligozoospermia

1.Prostate midline (utricular/mullerian) cyst

Mechanism: Large cyst may lead to azoospermia by compression of ejaculatory ducts

Utility for couple management:
-cyst aspiration may lead to normal semen parameters and natural conception, avoiding TESE and ICSI

Long term implications:
-cyst may increase again:
US and new aspiration required
-no sperm recovery after aspiration → TESE

Online Submissions: http://www.wjgnet.com/1949-8470office
wjr@wjgnet.com
doi:10.4329/wjr.v2.i5.172

World J Radiol 2010 May 28; 2(5): 172-179
ISSN 1949-8470 (online)
© 2010 Baishideng. All rights reserved.

GUIDELINES FOR CLINICAL PRACTICE

Imaging in male-factor obstructive infertility

Ragab H Donkol

Transrectal ultrasound

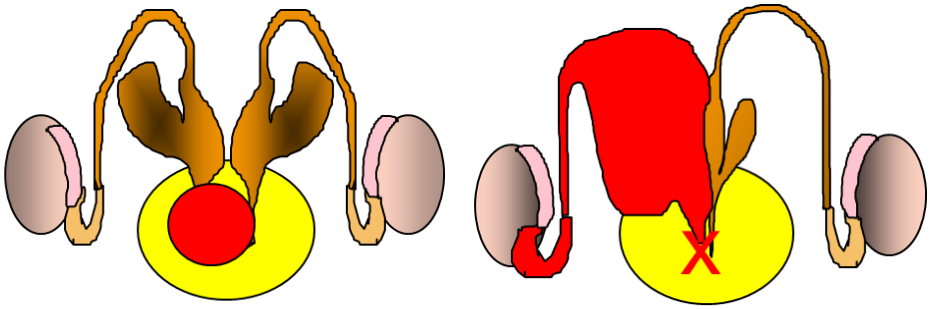

Clinical utility:

High:
a.Assessment of **obstructive azoospermia**/severe oligozoospermia

2.Ejaculatory ducts (ED) abnormalities: dilation (> 2 mm), cyst, calcification

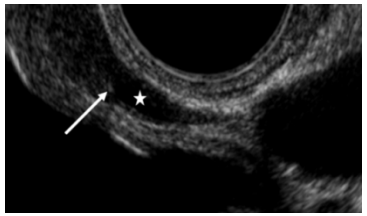

Mechanism: **seminal tract obtruction**

Utility for couple management:
-surgical treatment may lead to semen parameters improvement and natural conception, avoiding TESE and ICSI
-surgery indicated for ED cysts; a few Centers perform ED surgery

Long term implications:
-ED may close again → TESE
-no sperm recovery after surgery → TESE

Ejaculatory duct obstruction
Harry Fisch, Young M. Kang, Christopher W. Johnson and Erik T. Goluboff

Current Opinion in Urology 2002, 12:509–515

Transrectal ultrasound



Clinical utility:

High:
a.Assessment of **obstructive azoospermia**/severe oligozoospermia

3.Congenital bilateral absence of vas deferens (along with scrotal US)

Mechanism: **obstruction**

Utility: **indication for TESE (good prognosis: testes usually normal)**

Long term implications:
-screening for CFTR mutations
-screening for kidney agenesis/abnormalities
-screening for seminal vesicles presence/absence

Physical deformities relevant to male infertility

Rajender Singh, Alaa J. Hamada, Laura Bukavina and Ashok Agarwal

Nat. Rev. Urol. **9**, 156–174 (2012)

Transrectal ultrasound

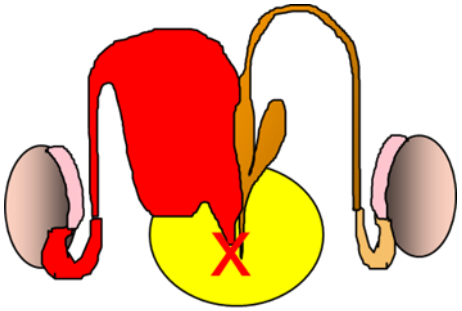

Clinical utility:

High:
a.Assessment of **obstructive azoospermia**/severe oligozoospermia

Indirect additional signs

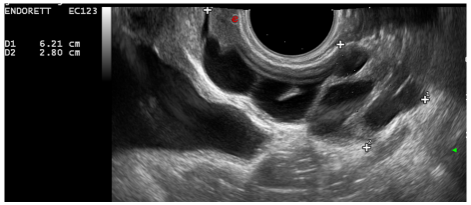

Seminal vesicles
-dilation (anterior-posterior diameter > 15 mm) after ej.

-contraction impairment
Low/no difference of seminal vesicles volume before and after ej.

Deferential ampullas: dilated (> 6 mm)

Human Reproduction, Vol.27, No.4 pp. 974–982, 2012
Advanced Access publication on February 16, 2012 doi:10.1093/humrep/des032

human reproduction ORIGINAL ARTICLE *Andrology*

Seminal vesicles ultrasound features in a cohort of infertility patients

F. Lotti[1], G. Corona[1,2], G.M. Colpi[3], E. Filimberti[1], S. Degli Innocenti[1], M. Mancini[3], E. Baldi[1], I. Noci[4], G. Forti[1], and M. Maggi[1,*]

Transrectal ultrasound

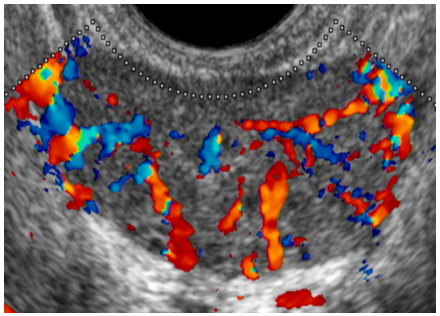

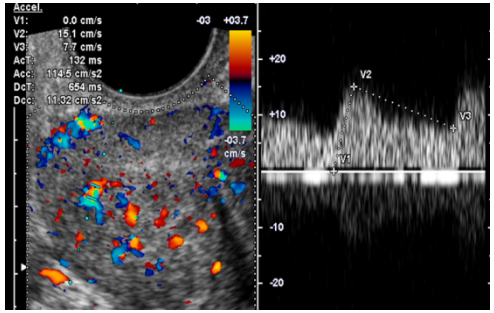

Clinical utility:

Moderate:
b.Assessment of prostate-vesicular inflammation, virtually leading to abnormal semen parameters (debated)

Transrectal ultrasound

Clinical utility:

Low:
c.Information on hypogonadism, biological response to treatment and assessment of treatment-related risk
❖ clinical and hormonal information may be sufficient, but…

-US detects low prostate volume (< 15-20 ml, or abnormally small for age)

-prostate volume and seminal vesicles increase with hCG or testosterone

Testosterone replacement therapy and prostate/seminal vesicle volume in Klinefelter's syndrome.
Sasagawa I, Nakada T, Kazama T, Terada T, Katayama T.
Arch Androl. **1989**;22(3):245-9.

Volume change of the prostate and seminal vesicles in male hypogonadism after androgen replacement therapy.
Sasagawa I, Nakada T, Kazama T, Satomi S, Terada T, Katayama T.
Int Urol Nephrol. **1990**;22(3):279-84.

-US detects for prostate cancer ?
low accuracy/no guidelines indication

N. Mottet (Chair), J. Bellmunt, E. Briers (Patient Representative), M. Bolla, P. Cornford (Vice-chair), M. De Santis, A. Henry, S. Joniau, T. Lam, M.D. Mason, V. Matveev, H. van der Poel, T.H. van der Kwast, O. Rouvière, T. Wiegel
Guidelines Associates: R.C.N. van den Bergh, T. van den Broeck, N.J. van Casteren, W. Everaerts, L. Marconi, P. Moldovan

➢ Scrotal ultrasound

Clinical utility: high in specific conditions

a. Assessment of scrotal features when physical examination unreliable

b. Assessment of testicular features

c. Assessment of epididymis / vas deferens

d. Assessment of varicocele

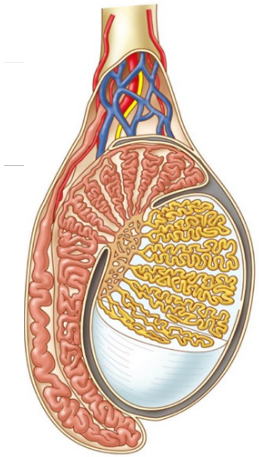

Human Reproduction Update, Vol.21, No.1 pp. 56–83, 2015
Advanced Access publication on July 19, 2014 doi:10.1093/humupd/dmu042

human reproduction update

Ultrasound of the male genital tract in relation to male reproductive health

Francesco Lotti and Mario Maggi*
Sexual Medicine and Andrology Unit, Department of Experimental and Clinical Biomedical Sciences, University of Florence, Florence, Italy

Scrotal ultrasound

Clinical utility:

a.Assessment of scrotal features when physical examination unreliable

-large hydrocele

-inguinal testis

-small testis

-epididymal enlargment

-scrotal skin thikness

Human Reproduction Update, Vol.21, No.1 pp. 56–83, 2015
Advanced Access publication on July 19, 2014 doi:10.1093/humupd/dmu042

human reproduction update

Ultrasound of the male genital tract in relation to male reproductive health

Francesco Lotti and Mario Maggi*
Sexual Medicine and Andrology Unit, Department of Experimental and Clinical Biomedical Sciences, University of Florence, Florence, Italy

Scrotal ultrasound

Clinical utility:

b.Assessment of testicular features

-testis localization / cryptorchidism

-testis volume

-testis inhomogenicity

-testis lesions

-testis vascularization

Scrotal ultrasound

Clinical utility:

b.Assessment of testicular features

-testis localization / cryptorchidism

Utility for:
-cryptorchid testis below internal inguinal ring (not abdominal)
-cancer detection
-follow-up of cryptorchid and contralateral testis

ELSEVIER

Seminars in ULTRASOUND CT and MRI

The Undescended Testis

Jared D. Christensen, MD, and Vikram S. Dogra, MD

Semin Ultrasound CT MRI 28:307-316 © 2007

PEDIATRICS®
OFFICIAL JOURNAL OF THE AMERICAN ACADEMY OF PEDIATRICS

REVIEW ARTICLES

Diagnostic Performance of Ultrasound in Nonpalpable Cryptorchidism: A Systematic Review and Meta-analysis

AUTHORS: Gregory E. Tasian, MD, MSc, and Hillary L. Copp, MD, MS

Pediatrics 2011;127:119

Scrotal ultrasound

Clinical utility:

b.Assessment of testicular features

-testis volume:

- **Utility: when unreliable physical examination is unreliable**
- **Often low utility: Prader gives sufficient information**

Relationship of Testis Size and LH Levels with Incidence of Major Adverse Cardiovascular Events in Older Men with Sexual Dysfunction

Giulia Rastrelli, MD, PhD,* Giovanni Corona, MD, PhD,*† Francesco Lotti, MD,* Valentina Boddi, MD,* Edoardo Mannucci, MD,‡ and Mario Maggi, MD*

J Sex Med 2013;10:2761–2773

N= 445 males of infertile couples

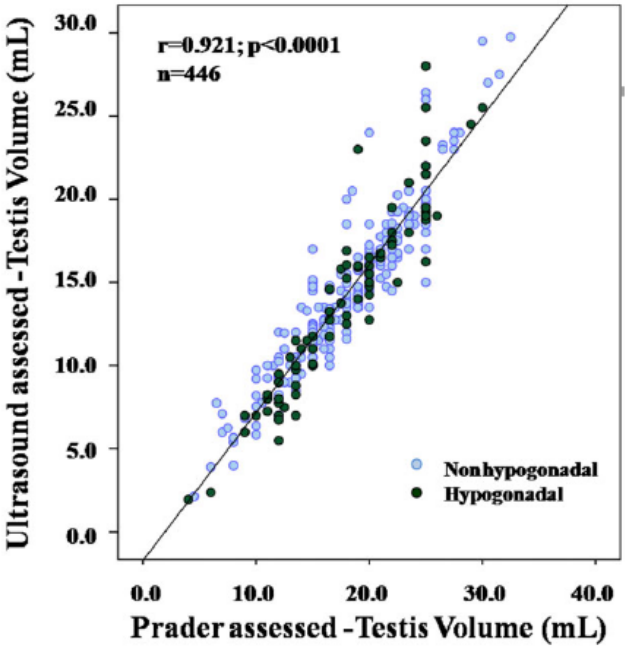

Scrotal ultrasound

Clinical utility:

b.Assessment of testicular features

-testis volume: low utility in (micro)TESE decision making, since it is performed even with small testes or karyotype abnormalities

Asian Journal of Andrology (2013) 15, 35–39
© 2013 AJA, SIMM & SJTU. All rights reserved 1008-682X/13 $32.00
www.nature.com/aja

REVIEW

Microdissection testicular sperm extraction: an update

Ali A Dabaja and Peter N Schlegel

Severe Testicular Atrophy does not Affect the Success of Microdissection Testicular Sperm Extraction

Campbell F. Bryson, Ranjith Ramasamy, Matthew Sheehan, Gianpiero D. Palermo, Zev Rosenwaks and Peter N. Schlegel*,†

0022-5347/14/1911-0175/0
THE JOURNAL OF UROLOGY®
© 2014 by American Urological Association Education and Research, Inc.
http://dx.doi.org/10.1016/j.juro.2013.07.065
Vol. 191, 175-178, January 2014
Printed in U.S.A.

Scrotal ultrasound

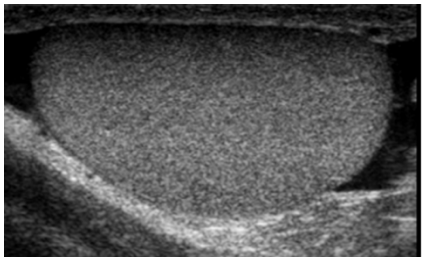

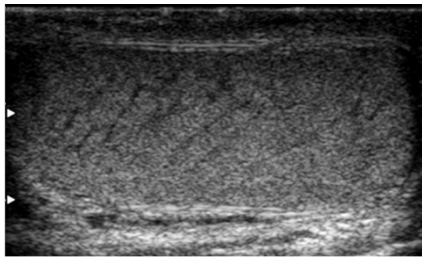

Clinical utility:

b.Assessment of testicular features

-testis inhomogeneity

- **Association with worse sperm parameters**
- **If association with «additional risk factors» (cryptorchidism, microcalcifications): higher risk for tumors**

PICTORIAL ESSAY

Striated Appearance of the Testes

Norman Loberant, MD, Shweta Bhatt, MD,† Gregory T. McLennan, MD,‡ and Vikram S. Dogra, MD†*

(*Ultrasound Quarterly* 2010;26:37–44)

Scrotal ultrasound

Clinical utility:

b.Assessment of testicular features

-testis lesions

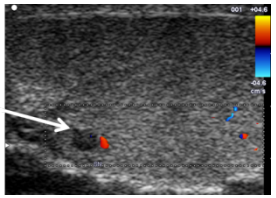

- **Nodular areas**

Differential diagnosis with cysts or extratesticular findings

- **Small lesions → follow-up**
- **Large lesions→ surgery**

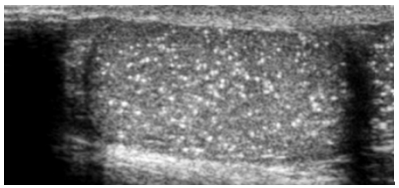

- **Calcifications**
- **Isolated: no follow-up**
- **> 5 microcalcification/US field (microlithiasis): follow-up if «additional risk factors»**

European Association of Urology

Guidelines Back

Individual Guidelines

Oncology Guidelines

Home › Testicular Cancer

Testicular Cancer

P. Albers (Chair), W. Albrecht, F. Algaba, C. Bokemeyer, G. Cohn-Cedermark, K. Fizazi, A. Horwich, M.P. Laguna, N. Nicolai, J. Oldenburg

Eur Radiol
DOI 10.1007/s00330-012-2520-4

UROGENITAL

Testicular microlithiasis: is there a need for surveillance in the absence of other risk factors?

Jonathan Richenberg · Nick Brejt

Eur Radiol. 2012;22:2540-6

Scrotal ultrasound

Clinical utility:

b.Assessment of testicular features

-testis vascularization

1.Absent
Torsion

2.Enhanced

Diffuse
Orchitis
Tumors (limphoma, leukemia)

Focal
tumors

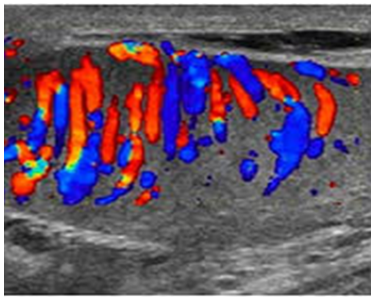

Human Reproduction Update, Vol.21, No.1 pp. 56–83, 2015
Advanced Access publication on July 19, 2014 doi:10.1093/humupd/dmu042
human reproduction update

Ultrasound of the male genital tract in relation to male reproductive health

Francesco Lotti and Mario Maggi*
Sexual Medicine and Andrology Unit, Department of Experimental and Clinical Biomedical Sciences, University of Florence, Florence, Italy

Scrotal ultrasound

Clinical utility:

c.Assessment of epididymal / vas deferens

-agenesis

-enlargment (obstruction, inflammation)

-hyperemia (inflammation)

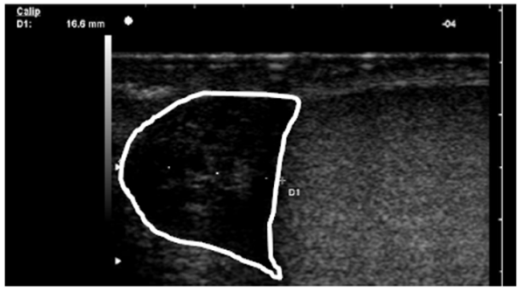

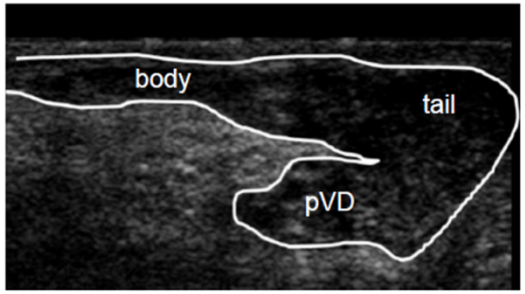

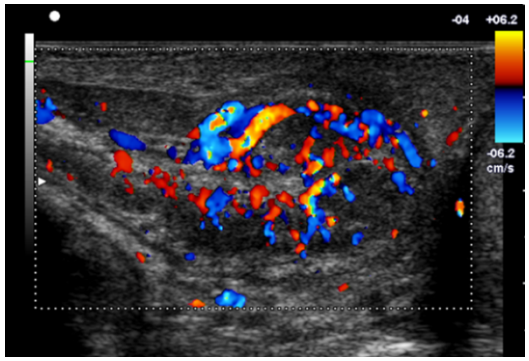

Contents lists available at ScienceDirect

European Journal of Radiology

journal homepage: www.elsevier.com/locate/ejrad

Acute epididymitis in ultrasound: Results of a prospective study with baseline and follow-up investigations in 134 patients

A. Pilatz[a,*], F. Wagenlehner[a,1], T. Bschleipfer[a,2], H.-C. Schuppe[a,3], T. Diemer[a,4], T. Linn[b,5], W. Weidner[a,6], B. Altinkilic[a,7]

Eur J Radiol. 2013 ;82:e762-8.

Physical deformities relevant to male infertility

Rajender Singh, Alaa J. Hamada, Laura Bukavina and Ashok Agarwal

Nat. Rev. Urol. 9, 156–174 (2012)

Scrotal ultrasound

Clinical utility:

Report on varicocele and infertility

*The Practice Committee of the American Society for Reproductive Medicine**

Birmingham, Alabama

Controversies regarding diagnosis and treatment of varicoceles in male partners in infertile couples are considered in detail. (Fertil Steril® 2008;90:S247–9. ©2008 by American Society for Reproductive Medicine.)

Guidelines on Male Infertility

A. Jungwirth (chair), T. Diemer, G.R. Dohle, A. Giwercman, Z. Kopa, H. Tournaye, C. Krausz

European Association of Urology

© European Association of Urology 2013

AUA/ASRM and EAU

d.Assessment of varicocele

-clinical evaluation is sufficient for clinical decision
→ surgery if grade II-III

-CDUS evaluates persistent venous reflux, avoiding «false varicocele» (venous dilation without reflux)

-CDUS useful in evaluating venous reflux recurrence/persistence after surgery

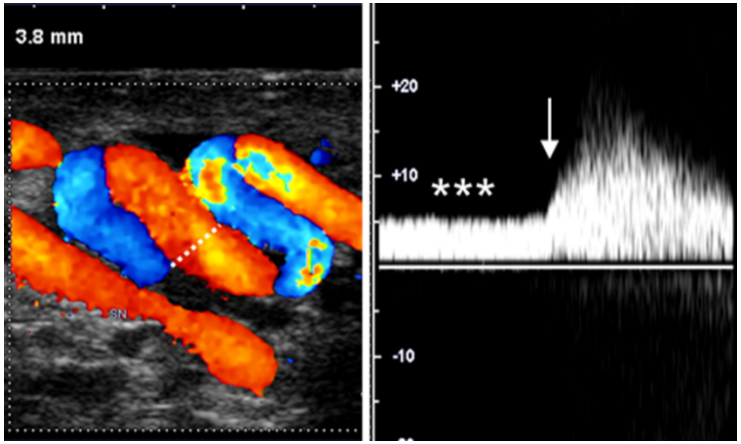

Is selective internal spermatic venography necessary in detecting recurrent varicocele after surgical repair?

Tefekli A, Cayan S, Uluocak N, Poyanli A, Alp T, Kadioğlu A.
Eur Urol. **2001** Oct;40(4):404-8.

Role of male genital tract (MGT) color-Doppler ultrasound (CDUS)

2.Male accessory gland infection (MAGI)



EAU Guidelines on Chronic Pelvic Pain

D. Engeler (Chair), A.P. Baranowski, J. Borovicka,
P. Dinis-Oliveira, S. Elneil, J. Hughes,
E.J. Messelink (Vice-chair), A.C. de C Williams
Guidelines Associates: A. Cottrell, S. Goonewardene

© European Association of Urology 2016

European Association of Urology

Ultrasound

Has limited value but may reassure patients. However, over-investigating may be detrimental.

- EAU Guidelines: CDUS → limited value

Guidelines on Urological Infections

European Association of Urology

M. Grabe (chairman), T.E. Bjerklund-Johansen, H. Botto, M. Çek, K.G. Naber, R.S. Pickard, P. Tenke, F. Wagenlehner, B. Wullt

© European Association of Urology 2016

10. BACTERIAL PROSTATITIS

10.3.5 Other tests

Transrectal ultrasound (TRUS) may reveal intraprostatic abscesses, calcification in the prostate, and dilatation of the seminal vesicles but is unreliable and cannot be used as a diagnostic tool in prostatitis (17).

11. EPIDIDYMITIS AND ORCHITIS

11.6.1 Differential diagnosis

It is imperative for the physician to differentiate between epididymitis and spermatic cord torsion as soon as possible using all available information, including the age of the patient, history of urethritis, clinical evaluation and Doppler (duplex) scanning of testicular blood flow.

- However, there is increasing evidence of an important role of CDUS in MGT inflammation

Human Reproduction Update, Vol.21, No.1 pp. 56–83, 2015
Advanced Access publication on July 19, 2014 doi:10.1093/humupd/dmu042
human reproduction update

Ultrasound of the male genital tract in relation to male reproductive health

Francesco Lotti and Mario Maggi*
Sexual Medicine and Andrology Unit, Department of Experimental and Clinical Biomedical Sciences, University of Florence, Florence, Italy

Journal of Reproductive Immunology 100 (2013) 54–65
Contents lists available at ScienceDirect
Journal of Reproductive Immunology
journal homepage: www.elsevier.com/locate/jreprimm

Interleukin 8 and the male genital tract

Francesco Lotti*, Mario Maggi

Contents lists available at ScienceDirect
European Journal of Radiology
journal homepage: www.elsevier.com/locate/ejrad

Acute epididymitis in ultrasound: Results of a prospective study with baseline and follow-up investigations in 134 patients

A. Pilatz[a,*], F. Wagenlehner[a,1], T. Bschleipfer[a,2], H.-C. Schuppe[a,3], T. Diemer[a,4], T. Linn[b,5], W. Weidner[a,6], B. Altinkilic[a,7]

Eur J Radiol. 2013 Dec;82(12):e762-8.

ANDROLOGY

Seminal, clinical and colour-Doppler ultrasound correlations of prostatitis-like symptoms in males of infertile couples

[1]F. Lotti, [1,2]G. Corona, [3]N. Mondaini, [1]E. Maseroli, [1]M. Rossi, [1]E. Filimberti, [4]I. Noci, [1]G. Forti and [1]M. Maggi

Andrology, 2014, 2, 30–41

AJR FOCUS ON:

Imaging of Acute and Emergent Genitourinary Conditions: What the Radiologist Needs to Know

Jennifer W. Uyeda[1]
Bradley S. Gans
Aaron Sodickson

AJR Am J Roentgenol. 2015 Jun;204(6):W631-9.

International Journal of Andrology
international journal of andrology ISSN 0105-6263

ORIGINAL ARTICLE

Ultrasonographic and clinical correlates of seminal plasma interleukin-8 levels in patients attending an andrology clinic for infertility

F. Lotti,*[1] G. Corona,*†[1] M. Mancini,‡ E. Filimberti,* S. Degli Innocenti,* G. M. Colpi,‡ E. Baldi,* I. Noci,§ G. Forti,* L. Adorini¶ and M. Maggi*

2010 European Academy of Andrology, 1–14

- The 90s

Ultrasonographic Findings in Prostatitis

Andrew Doble, F.R.C.S., and*
Simon St. C. Carter, M.B., F.R.C.S.†

Urologic Clinics of North America—Vol. 16, No. 4, November 1989

British Journal of Urology (1991), **67**, 173–176
© 1991 British Journal of Urology

Diagnosis of Chronic Abacterial Prostato-vesiculitis by Rectal Ultrasonography in Relation to Symptoms and Findings

E. CHRISTIANSEN and K. PURVIS

international journal of andrology, 18, Suppl. 2: 27–31 (1995)

Clinical relevance of scrotal and transrectal ultrasonography in andrological patients

H. M. BEHRE, S. KLIESCH, F. SCHÄDEL and E. NIESCHLAG

international journal of andrology, 16:1–13(1993)

Review

Infection in the male reproductive tract. Impact, diagnosis and treatment in relation to male infertility

K. PURVIS and E. CHRISTIANSEN

Human Reproduction vol.14 no.8 pp.2025–2030, 1999

Summary: US signs suggestive of MAGI

Seminal leukocyte concentration and related specific reactive oxygen species production in patients with male accessory gland infections

Vicari E.

Table I. Ultrasound findings considered indicative of male accessory gland infection

1. Prostatitis alone (P)
   The presence of two or more of the following US signs (Di Trapani *et al*., 1988; Doble and Carter, 1989; Christiansen and Purvis, 1991):
   a.1. glandular asymmetry
   b.1. hypoechogenicity associated with oedema
   c.1. hyperechogenicity associated with areas of calcification
   d.1. dilation of the periprostatic venous plexus
2. Prostato-vesiculitis (PV)
   In addition to the above-mentioned US inflammatory iuxta-prostate changes, fulfilled two or more of the following US signs (Di Trapani *et al*., 1988; Purvis and Christiansen, 1993):
   a.2. enlargement and assymetry
   b.2. thickening and calcification of the glandular epithelium
   c.2. areas of endocapsulation in the vesicle(s)
3. Prostato-vesiculo-epididymitis (PVE)
   The PV group-specific US signs associated with two or more of the following US signs (Purvis and Christiansen, 1993; Holden and List, 1994; Vicari and Mongioì, 1995):
   a.3. an increased size of the head (diameter cranio-caudal >12 mm) and/or tail (diameter cranio-caudal >6 mm) of the epididymis
   b.3. presence of multiple microcyst lesions confined to the epididymal head and/or tail
   c.3. oedematous hyperechoic epididymis
   d.3. a large hydrocele

US = ultrasound.

Prostate

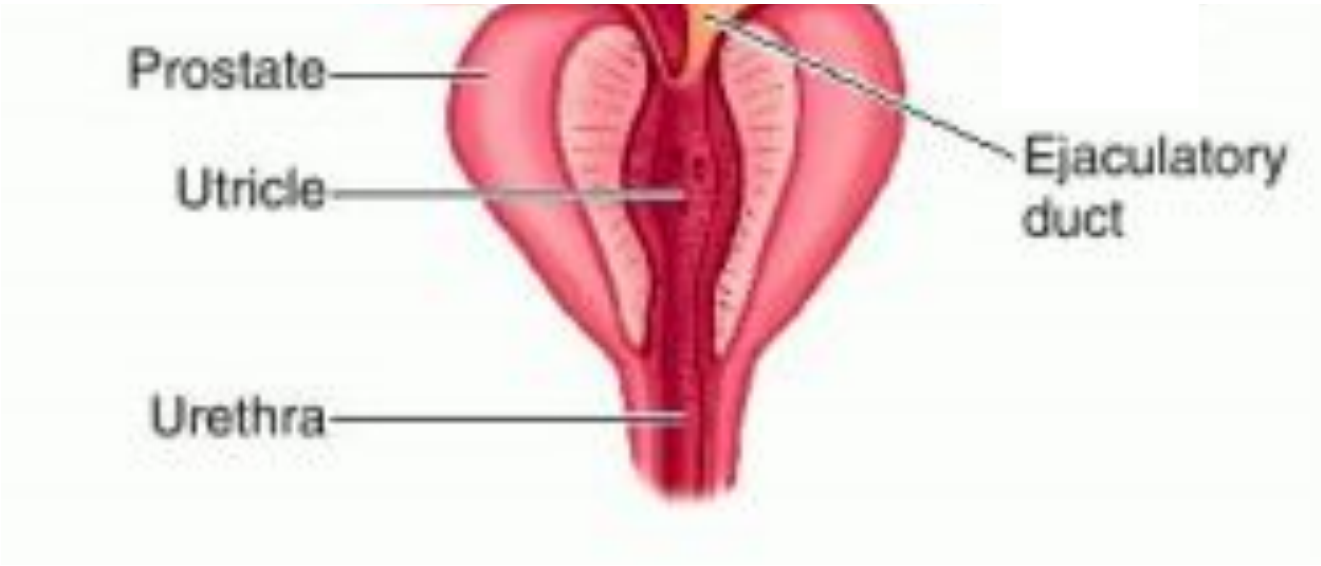

Prostate inflammation: conventional parameters

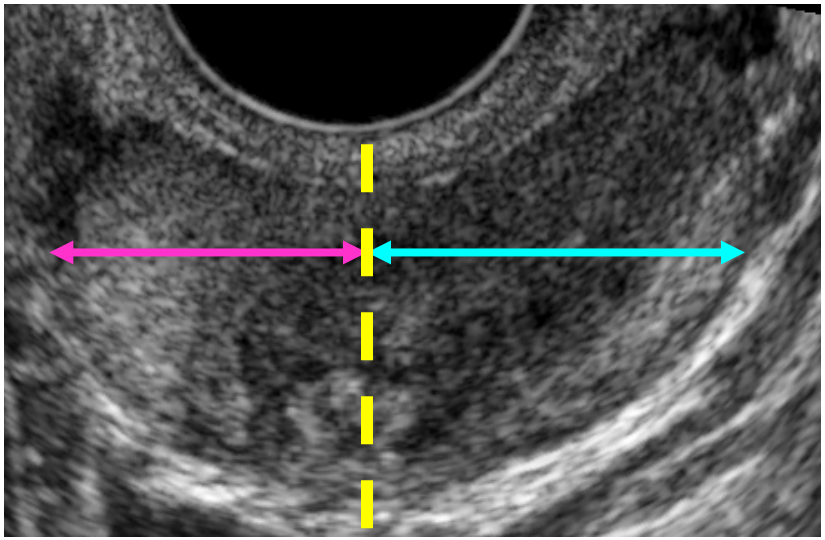

Asimmetry

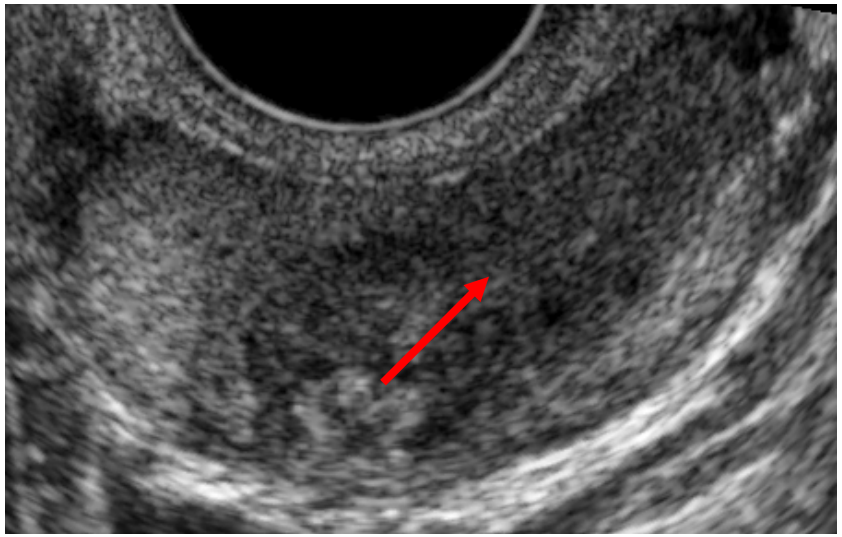

Hypoechoic (oedema)

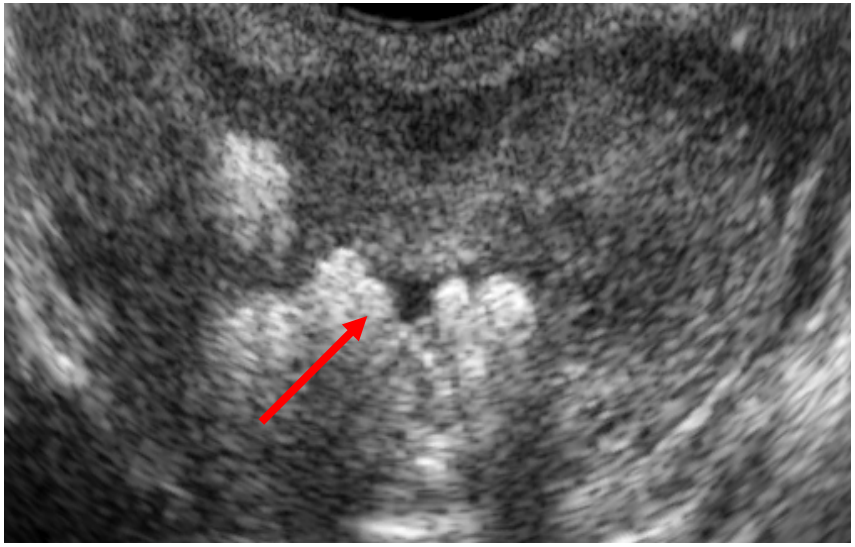

Hyperechogenicity/Calcifications

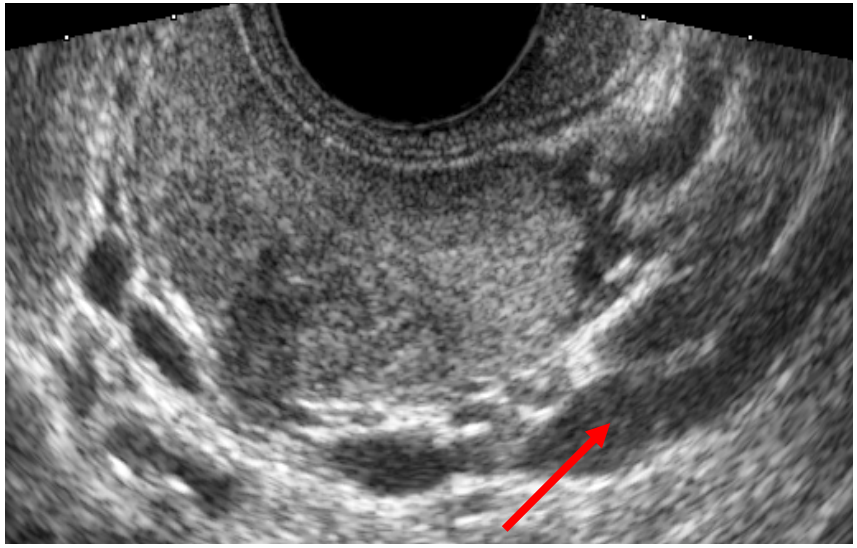

Periprostatic venous plexus dilation

Criticisms

-No cut-off for:

- Asimmetry
- Prostatic venous plexus

-Hypoechogenicity:
inter-operator variability

-Calcifications:
indicates mainly past infections/ chronic inflammation

Human Reproduction vol.14 no.8 pp.2025–2030, 1999

Seminal leukocyte concentration and related specific reactive oxygen species production in patients with male accessory gland infections

E.Vicari

Table I. Ultrasound findings considered indicative of male accessory gland infection

1. Prostatitis alone (P)
   The presence of two or more of the following US signs (Di Trapani *et al.*, 1988; Doble and Carter, 1989; Christiansen and Purvis, 1991):
   a.1. glandular asymmetry
   b.1. hypoechogenicity associated with oedema
   c.1. hyperechogenicity associated with areas of calcification
   d.1. dilation of the periprostatic venous plexus

Journal of Reproductive Immunology 100 (2013) 54–65

Contents lists available at ScienceDirect

Journal of Reproductive Immunology

journal homepage: www.elsevier.com/locate/jreprimm

ELSEVIER

Interleukin 8 and the male genital tract

Francesco Lotti*, Mario Maggi

International Journal of Andrology

international journal of andrology ISSN 0105-6263

ORIGINAL ARTICLE

Ultrasonographic and clinical correlates of seminal plasma interleukin-8 levels in patients attending an andrology clinic for infertility

F. Lotti,*[1] G. Corona,*†[1] M. Mancini,‡ E. Filimberti,* S. Degli Innocenti,* G. M. Colpi,‡ E. Baldi,* I. Noci,§ G. Forti,* L. Adorini¶ and M. Maggi*

Prostate calcifications

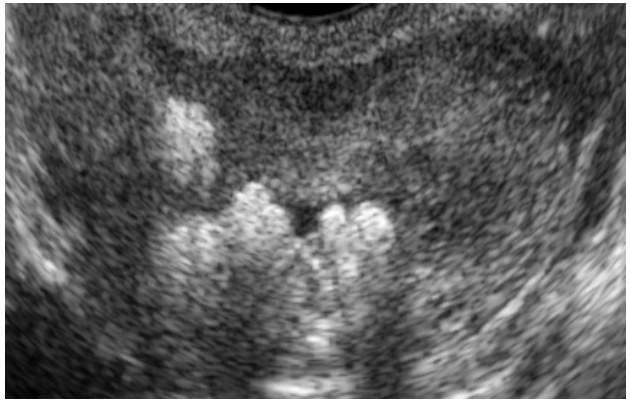

Association with MAGI
(Vicari, Hum Reprod, 1999, 14, 2025-2030
Vicari et al., J Endocrinol Invest, 2006, 29, 18-25.)

Association with high sIL-8 levels
(Lotti et al., Int J Androl, 2011; 34:600-13)

Maintainance prostatic inflammation in chronic prostatitis (CP)
(Meares. Urology, 1974, 4:560-566)

Association with bacteric colonization, maintainance and duration of symtoms in CP
(Shoskes et al., Urology 2007, 70:235-238)

High prevalence in affections with systemic inflammation: obesity and metabolic syndrome
(Lotti et al., J Endocrinol Invest 2011;34:e336-42)
Lotti et al., Asian J Androl, 2014 Mar-Apr;16(2):295-304)

Correlations with corpora amylacea (hystology on biopsy)
(Doble & Carter. Urol Clin North Am 1989, 16:763-772)

Corpora amylacea contain acuthe phase proteins in neutrophilic granules
(Sfanos et al., Proc Natl Acad Sci U S A. 2009, 106:3443-8)

Prostatic venous plexus

* Eur Urol 1988;15:230–234

© 1988 S. Karger AG, Basel
0302–2838/88/0154–0230$2.75/0

Chronic Prostatitis and Prostatodynia: Ultrasonographic Alterations of the Prostate, Bladder Neck, Seminal Vesicles and Periprostatic Venous Plexus

D. Di Trapani, C. Pavone, V. Serretta, N. Cavallo, G. Costa, M. Pavone-Macaluso
Department of Urology, University of Palermo, Italy

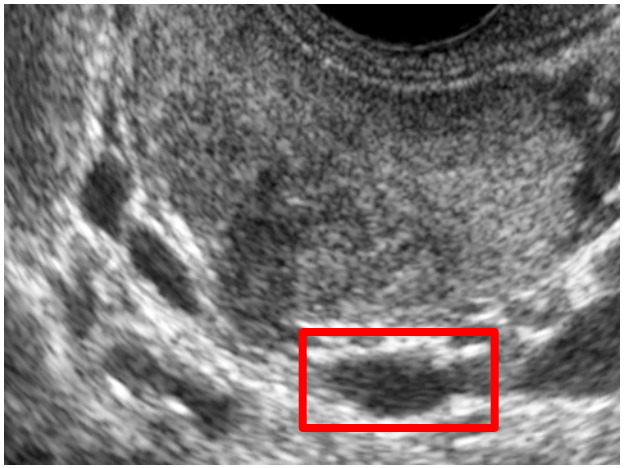

Section of the venous plexus > 150 mm^2
Not standardized, difficult to be reproduced

*

The Japanese Journal of Urology
日本泌尿器科学会雑誌
Japanese Urological Association

Nihon Hinyokika Gakkai Zasshi. 1996 Aug;87(8):1009-17.

[Clinical usefulness of transrectal sonography and transperineal color Doppler flow imaging in the diagnosis of intrapelvic venous congestion syndrome].

[Article in Japanese]
Kamoi K.

Dilation : diameter> 3 mm

*

J. Endocrinol. Invest. 34: e330-e335, 2011

Hypertrophic-congestive and fibro-sclerotic ultrasound variants of male accessory gland infection have different sperm output

S. La Vignera, E. Vicari, R. Condorelli, R. D'Agata, A.E. Calogero
Section of Endocrinology, Andrology and Internal Medicine, and Master in Andrological, Human Reproduction and Biotechnology Sciences, Department of Internal Medicine and Systemic Diseases, University of Catania, Catania, Italy

Only proposals,but no systematic studies

Dilation : diameter > 4 mm

Hypoechogenicity

International Journal of Andrology
international journal of andrology ISSN 0105-6263

ORIGINAL ARTICLE

Ultrasonographic and clinical correlates of seminal plasma interleukin-8 levels in patients attending an andrology clinic for infertility

F. Lotti,*[1] G. Corona,*†[1] M. Mancini,‡ E. Filimberti,* S. Degli Innocenti,* G. M. Colpi,‡ E. Baldi,* I. Noci,§ G. Forti,* L. Adorini¶ and M. Maggi*

High sIL-8 levels

ANDROLOGY

Seminal, clinical and colour-Doppler ultrasound correlations of prostatitis-like symptoms in males of infertile couples

[1]F. Lotti, [1,2]G. Corona, [3]N. Mondaini, [1]E. Maseroli, [1]M. Rossi, [1]E. Filimberti, [4]I. Noci, [1]G. Forti and [1]M. Maggi

Andrology, 2014, 2, 30–41

Prostatitis-like symptoms

J. Endocrinol. Invest. 34: e330-e335, 2011

Hypertrophic-congestive and fibro-sclerotic ultrasound variants of male accessory gland infection have different sperm output

S. La Vignera, E. Vicari, R. Condorelli, R. D'Agata, A.E. Calogero

Leukocytospermia and high ROS levels

J. Endocrinol. Invest. 34: e330-e335, 2011

Hypertrophic-congestive and fibro-sclerotic ultrasound variants of male accessory gland infection have different sperm output

S. La Vignera, E. Vicari, R. Condorelli, R. D'Agata, A.E. Calogero

Hypertrophic-congestive

- prostate: increase of volume, areas of ipoechogenicity, dilatation of peri-prostatic venous plexus, single or multiple internal similar cystis areas;

Fibro-sclerotic

- prostate: areas of hyperechogenicity, asimmetry of the gland volume;

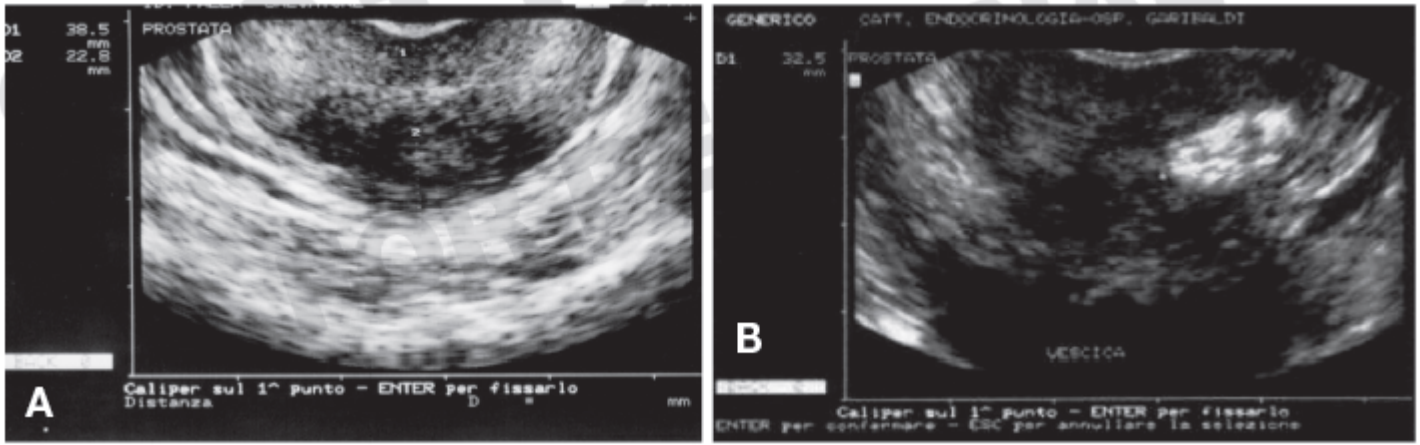

Prostate inflammation: new (dynamic) parameters

J Urol. 2000 Apr;163(4):1130-3.

Prostate blood flow characteristics in the chronic prostatitis/pelvic pain syndrome.

Cho IR[1], Keener TS, Nghiem HV, Winter T, Krieger JN.

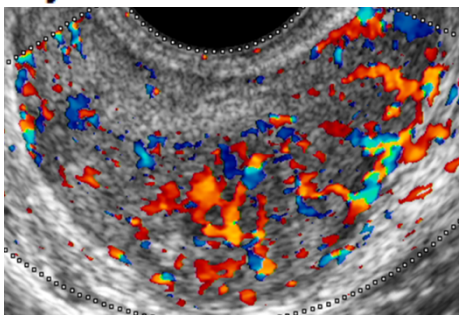

- Hyperemia: ≥ 15 vascular spot

ANDROLOGY

ISSN: 2047-2919

ANDROLOGY

ORIGINAL ARTICLE

Correspondence:
Mario Maggi, Sexual Medicine and Andrology Unit, Department of Experimental and Clinical Biomedical Sciences, University of Florence, Viale Pieraccini 6, Florence 50139, Italy.
E-mail: m.maggi@dfc.unifi.it

Keywords:
male infertility, National Institutes of Health-Chronic Prostatitis Symptom Index, prostatitis-like symptoms, scrotal and transrectal colour-Doppler ultrasound, seminal and laboratory parameters

Seminal, clinical and colour-Doppler ultrasound correlations of prostatitis-like symptoms in males of infertile couples

[1]F. Lotti, [1,2]G. Corona, [3]N. Mondaini, [1]E. Maseroli, [1]M. Rossi, [1]E. Filimberti, [4]I. Noci, [1]G. Forti and [1]M. Maggi

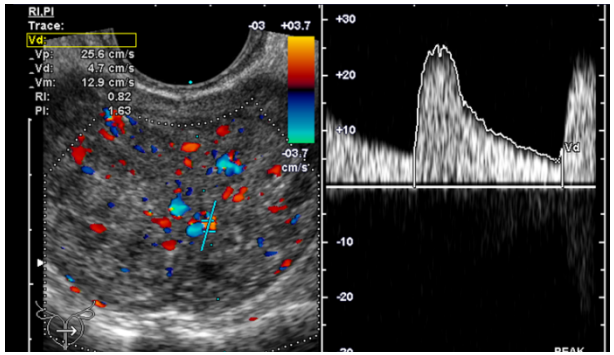

- Arterial peak systolyc velocity

Signs of current inflammation

Artery PSV: inflammatory parameter described in other organs

Thyroid

(Lagalla et al., Eur J Radiol 1998, 27:S149-56
Corona et al., Endocrine J, 2008, 55:345-350)

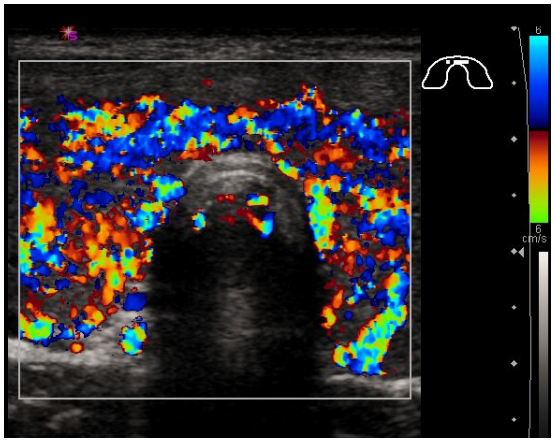

Exocrine glands

(Giovagnorio et al., J Ultrasound Med, 2000, 19:505-509.
Carotti et al., Clin Rheumatol, 2001, 20:213-219)

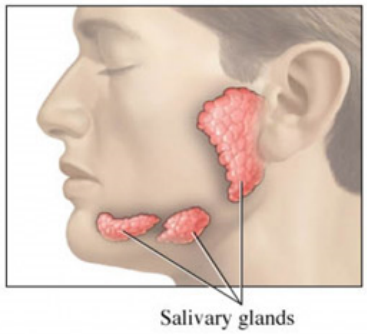

Sinovial membranes/joints

(Carotti et al., Ultrasound Med Biol, 2005, 31:739-473.
Carotti et al., Eur J Radiol 2012; 81:1834-8)

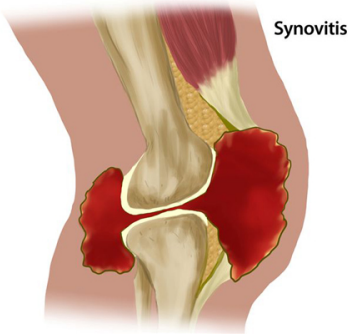

Prostate inflammation: dynamic parameters

Evaluation before ejaculation

Prostate Vascular Flow: The Effect of Ejaculation as Revealed on Transrectal Power Doppler Sonography

Thomas S. Keener[1]
Thomas C. Winter[1,2]
Richard Berger[3]
John N. Krieger[3]
Cynthia Nodell[1,4]
Ivan Rothman[3]
Hanh V. Nghiem[1,5]

AJR:175, October 2000

CONCLUSION. Transrectal sonography revealed that prostate vascular flow increases dramatically after ejaculation and remains elevated for at least 24 hr. This observation should be considered when power Doppler sonography is used to assess for potential hyperemia in patients suspected of having prostate abnormalities.

Hyperemia (semi-quantitative parameter)

J Urol. 2000 Apr;163(4):1130-3.

Prostate blood flow characteristics in the chronic prostatitis/pelvic pain syndrome.

Cho IR[1], Keener TS, Nghiem HV, Winter T, Krieger JN.

≥ 15 vascular spots: inflammation

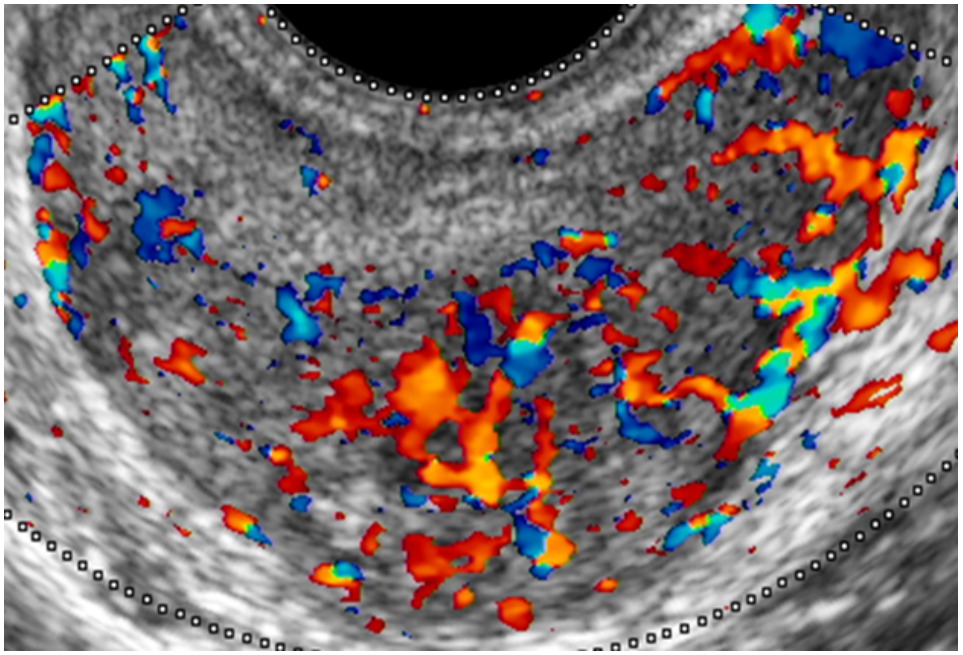

Prostate arterial peak systolic velocity (PSV)

ANDROLOGY

ISSN: 2047-2919

ANDROLOGY

ORIGINAL ARTICLE

Correspondence:
Mario Maggi, Sexual Medicine and Andrology Unit, Department of Experimental and Clinical Biomedical Sciences, University of Florence, Viale Pieraccini 6, Florence 50139, Italy.
E-mail: m.maggi@dfc.unifi.it

Keywords:
male infertility, National Institutes of Health-Chronic Prostatitis Symptom Index, prostatitis-like symptoms, scrotal and transrectal colour-Doppler ultrasound, seminal and laboratory parameters

Received: 23-Jul-2013
Revised: 10-Oct-2013
Accepted: 11-Oct-2013

Seminal, clinical and colour-Doppler ultrasound correlations of prostatitis-like symptoms in males of infertile couples

[1]F. Lotti, [1,2]G. Corona, [3]N. Mondaini, [1]E. Maseroli, [1]M. Rossi, [1]E. Filimberti, [4]I. Noci, [1]G. Forti and [1]M. Maggi

[1]Sexual Medicine and Andrology Unit, Department of Experimental and Clinical Biomedical Sciences, University of Florence, Florence, [2]Endocrinology Unit, Maggiore-Bellaria Hospital, Bologna, [3]Santa Maria Annunziata Hospital, and [4]Department of Obstetrics and Gynecology, University of Florence, Florence, Italy

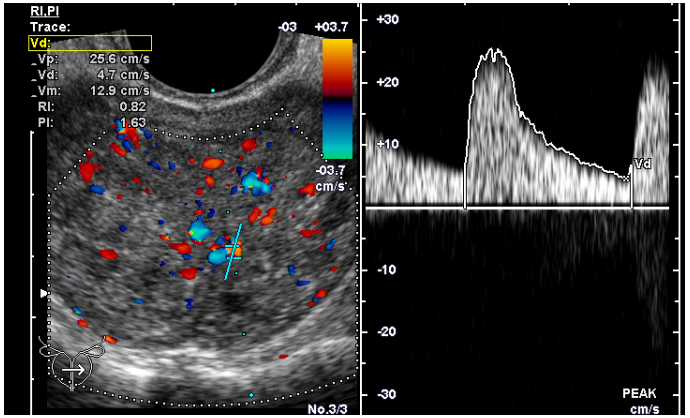

N = 400 (35.8±7.2 anni)

Prostatic arteries, transitional zone

Arterial PSV > 11 cm/s:
Moderate-severe prostatitis-like symptoms

Quantitative parameter in young men

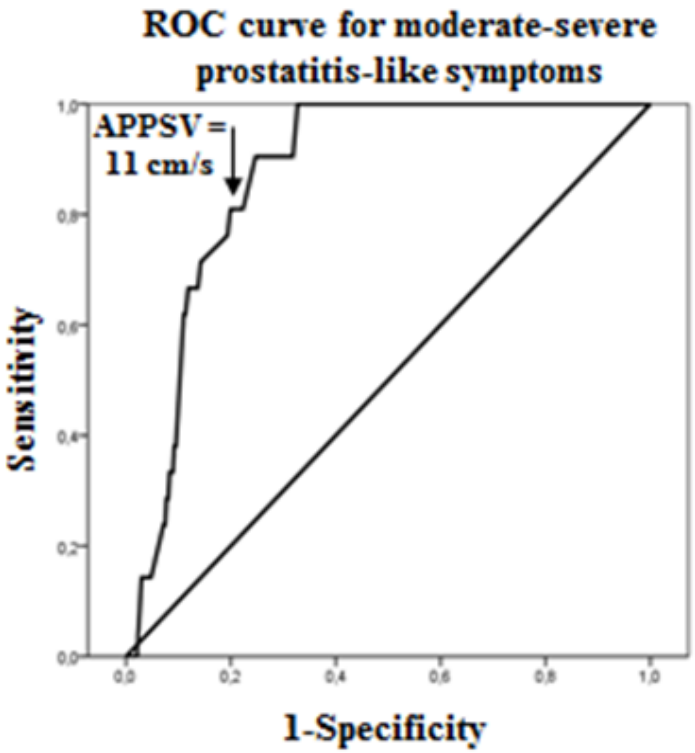

Vascular resistance in the prostate evaluated by colour Doppler ultrasonography: is benign prostatic hyperplasia a vascular disease?

ANDREAS P. BERGER, WOLFGANG HORNINGER, JASMIN BEKTIC, ALEXANDRE PELZER, ROBERT SPRANGER, GEORGE BARTSCH and FERDINAND FRAUSCHER*
*Departments of Urology and *Radiology, Medical University of Innsbruck, Austria*

2006 BJU INTERNATIONAL | 98, 587–590 |

Inflammation in BPH patients

PSV > 15 cm/s

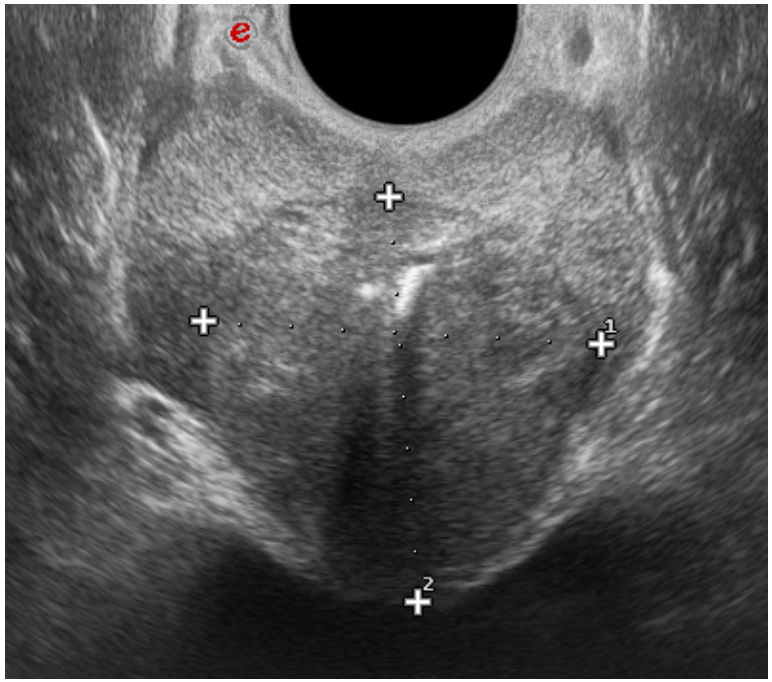

1.CDUS correlates of prostatitis-like symptoms

ANDROLOGY

ISSN: 2047-2919

ANDROLOGY

ORIGINAL ARTICLE

N = 400 (35.8±7.2 anni)

Correspondence:
Mario Maggi, Sexual Medicine and Andrology Unit, Department of Experimental and Clinical Biomedical Sciences, University of Florence, Viale Pieraccini 6, Florence 50139, Italy.
E-mail: m.maggi@dfc.unifi.it

Keywords:
male infertility, National Institutes of Health-Chronic Prostatitis Symptom Index, prostatitis-like symptoms, scrotal and transrectal colour-Doppler ultrasound, seminal and laboratory parameters

Received: 23-Jul-2013
Revised: 10-Oct-2013
Accepted: 11-Oct-2013

Seminal, clinical and colour-Doppler ultrasound correlations of prostatitis-like symptoms in males of infertile couples

[1]F. Lotti, [1,2]G. Corona, [3]N. Mondaini, [1]E. Maseroli, [1]M. Rossi, [1]E. Filimberti, [4]I. Noci, [1]G. Forti and [1]M. Maggi

[1]Sexual Medicine and Andrology Unit, Department of Experimental and Clinical Biomedical Sciences, University of Florence, Florence, [2]Endocrinology Unit, Maggiore-Bellaria Hospital, Bologna, [3]Santa Maria Annunziata Hospital, and [4]Department of Obstetrics and Gynecology, University of Florence, Florence, Italy

0022-5347/01/1653-0842/0
THE JOURNAL OF UROLOGY®
Copyright © 2001 by AMERICAN UROLOGICAL ASSOCIATION, INC.®
Vol. 165, 842–845, March 2001
Printed in U.S.A.

PREVALENCE OF PROSTATITIS-LIKE SYMPTOMS IN A POPULATION BASED STUDY USING THE NATIONAL INSTITUTES OF HEALTH CHRONIC PROSTATITIS SYMPTOM INDEX

J. CURTIS NICKEL,* JOE DOWNEY, DUNCAN HUNTER AND JANET CLARK

«Prostatitis-like symptoms (PLS)»:
perineal and/or ejaculatory pain or discomfort with NIH-CPSI pain score ≥ 4 (moderate-severe: ≥ 8)

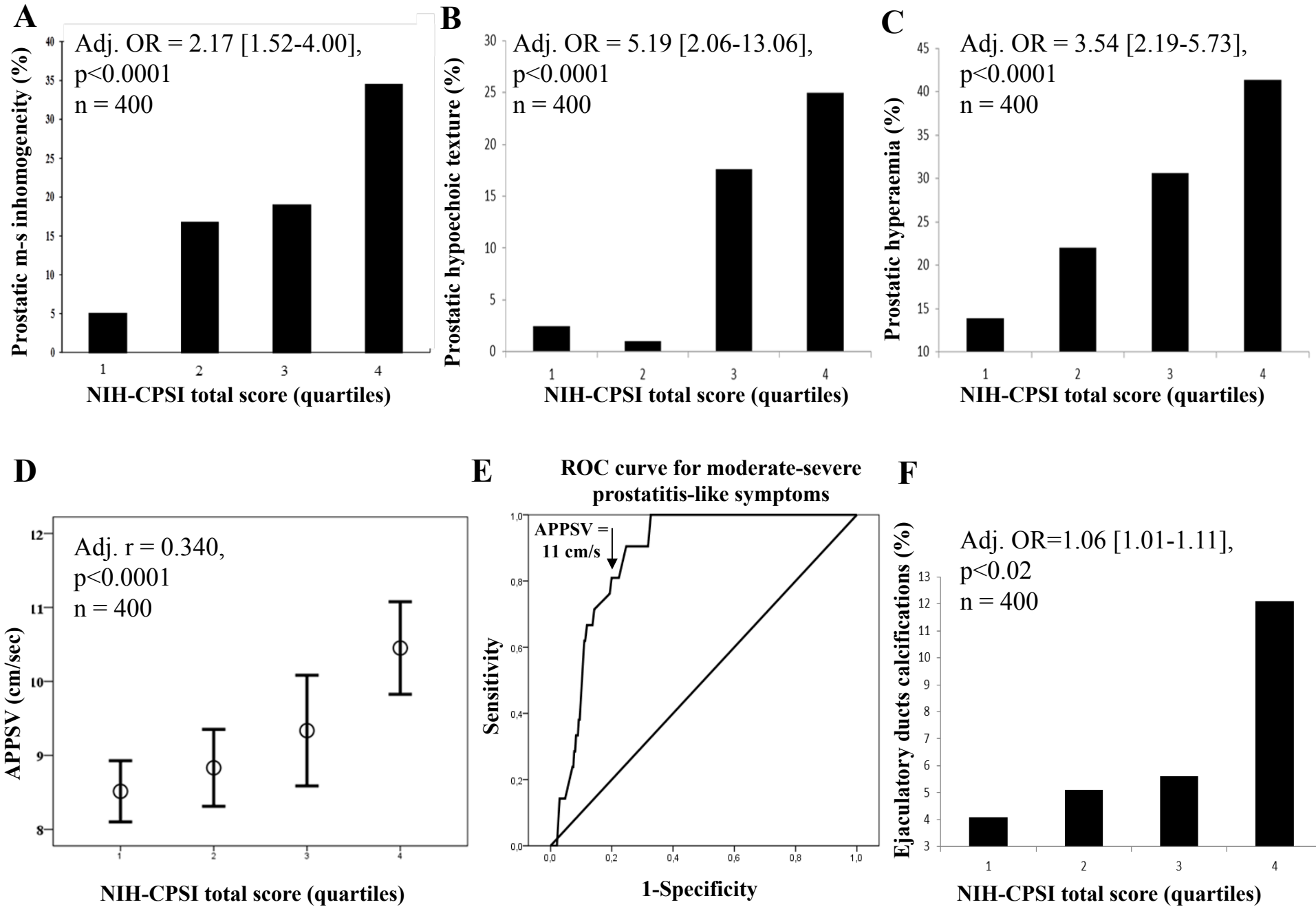
A
Adj. OR = 2.17 [1.52-4.00],
p<0.0001
n = 400
Prostatic m-s inhomogeneity (%)
NIH-CPSI total score (quartiles)
B
Adj. OR = 5.19 [2.06-13.06],
p<0.0001
n = 400
Prostatic hypoechoic texture (%)
NIH-CPSI total score (quartiles)
C
Adj. OR = 3.54 [2.19-5.73],
p<0.0001
n = 400
Prostatic hyperaemia (%)
NIH-CPSI total score (quartiles)
D
Adj. r = 0.340,
p<0.0001
n = 400
APPSV (cm/sec)
NIH-CPSI total score (quartiles)
E
ROC curve for moderate-severe prostatitis-like symptoms
APPSV = 11 cm/s
Sensitivity
1-Specificity
F
Adj. OR=1.06 [1.01-1.11],
p<0.02
n = 400
Ejaculatory ducts calcifications (%)
NIH-CPSI total score (quartiles)

Fig. 2

2.CDUS correlates of seminal interleukin 8 (sIL-8)

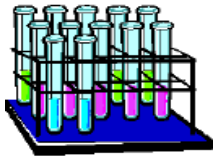

EUROPEAN UROLOGY 51 (2007) 524–533

available at www.sciencedirect.com
journal homepage: www.europeanurology.com

European Association of Urology

Infections

Seminal Plasma Cytokines and Chemokines in Prost Inflammation: Interleukin 8 as a Predictive Biomarke Chronic Prostatitis/Chronic Pelvic Pain Syndrome an Benign Prostatic Hyperplasia☆

Giuseppe Penna[a,1], *Nicola Mondaini*[b,1], *Susana Amuchastegui*[a], *Selene Degli Innocenti*[c], *Marco Carini*[b], *Gianluca Giubilei*[b], *Benedetta Fibbi*[a,c], *Enrico Colli*[a], *Mario Maggi*[c], *Luciano Adorini*[a,*]

IL-8:

-proinflammatory chemochine

-high expression in genital tract

-surrogate marker of prostate inflammation

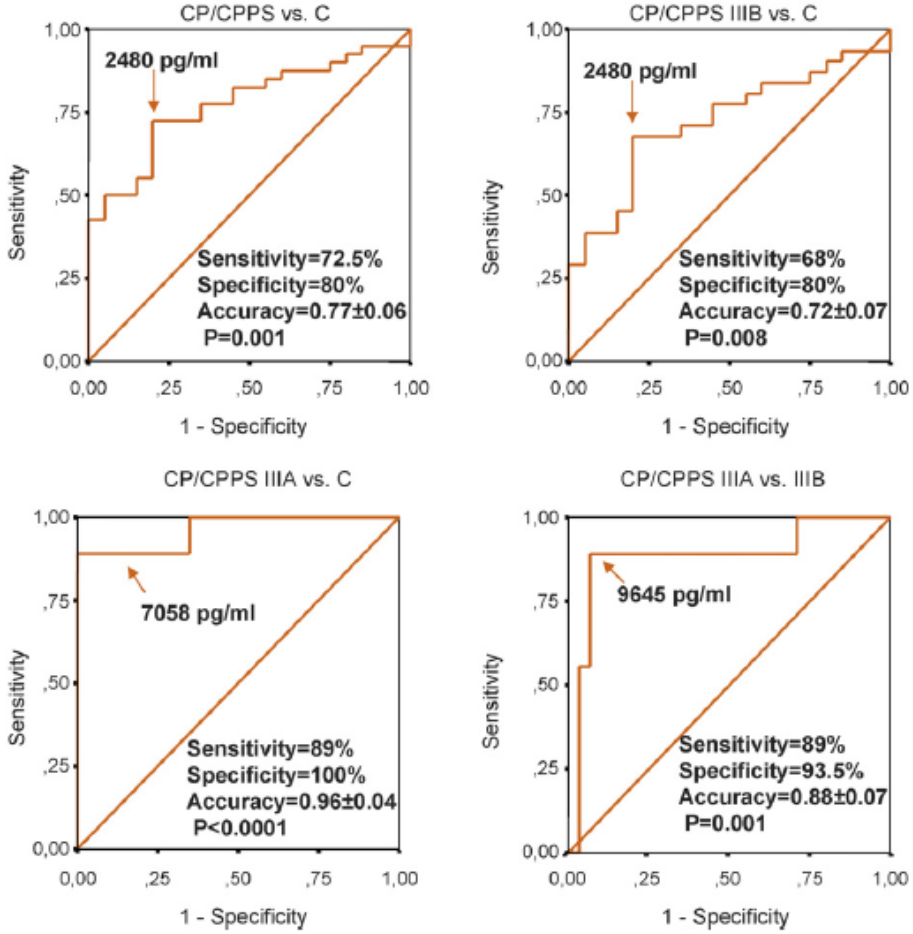

International Journal of Andrology

international journal of andrology ISSN 0105-6263

ORIGINAL ARTICLE

Ultrasonographic and clinical correlates of seminal plasma interleukin-8 levels in patients attending an andrology clinic for infertility

F. Lotti,*[1] G. Corona,*†[1] M. Mancini,‡ E. Filimberti,* S. Degli Innocenti,* G. M. Colpi,‡ E. Baldi,* I. Noci,§ G. Forti,* L. Adorini¶ and M. Maggi*

Journal of Reproductive Immunology 100 (2013) 54–65

ELSEVIER

Contents lists available at ScienceDirect

Journal of Reproductive Immunology

journal homepage: www.elsevier.com/locate/jreprimm

Interleukin 8 and the male genital tract

Francesco Lotti*, Mario Maggi

Sexual Medicine and Andrology Unit, Department of Clinical Physiopathology, University of Florence, Florence, Italy

High sIL-8 levels: entire «male genital tract» inflammation

International Journal of Andrology

international journal of andrology ISSN 0105-6263

ORIGINAL ARTICLE

Ultrasonographic and clinical correlates of seminal plasma interleukin-8 levels in patients attending an andrology clinic for infertility

F. Lotti,*[1] G. Corona,*†[1] M. Mancini,‡ E. Filimberti,* S. Degli Innocenti,* G. M. Colpi,‡ E. Baldi,* I. Noci,§ G. Forti,* L. Adorini¶ and M. Maggi*

Of 250 subjects seeking medical care for couple infertility,
79 men with MAGI
(mean age: 36.4 ± 7.5 years)

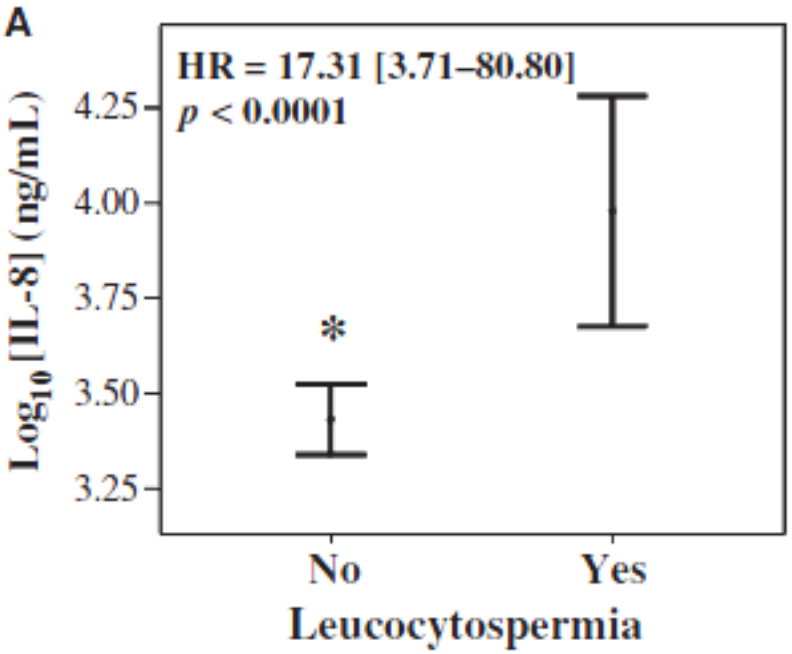

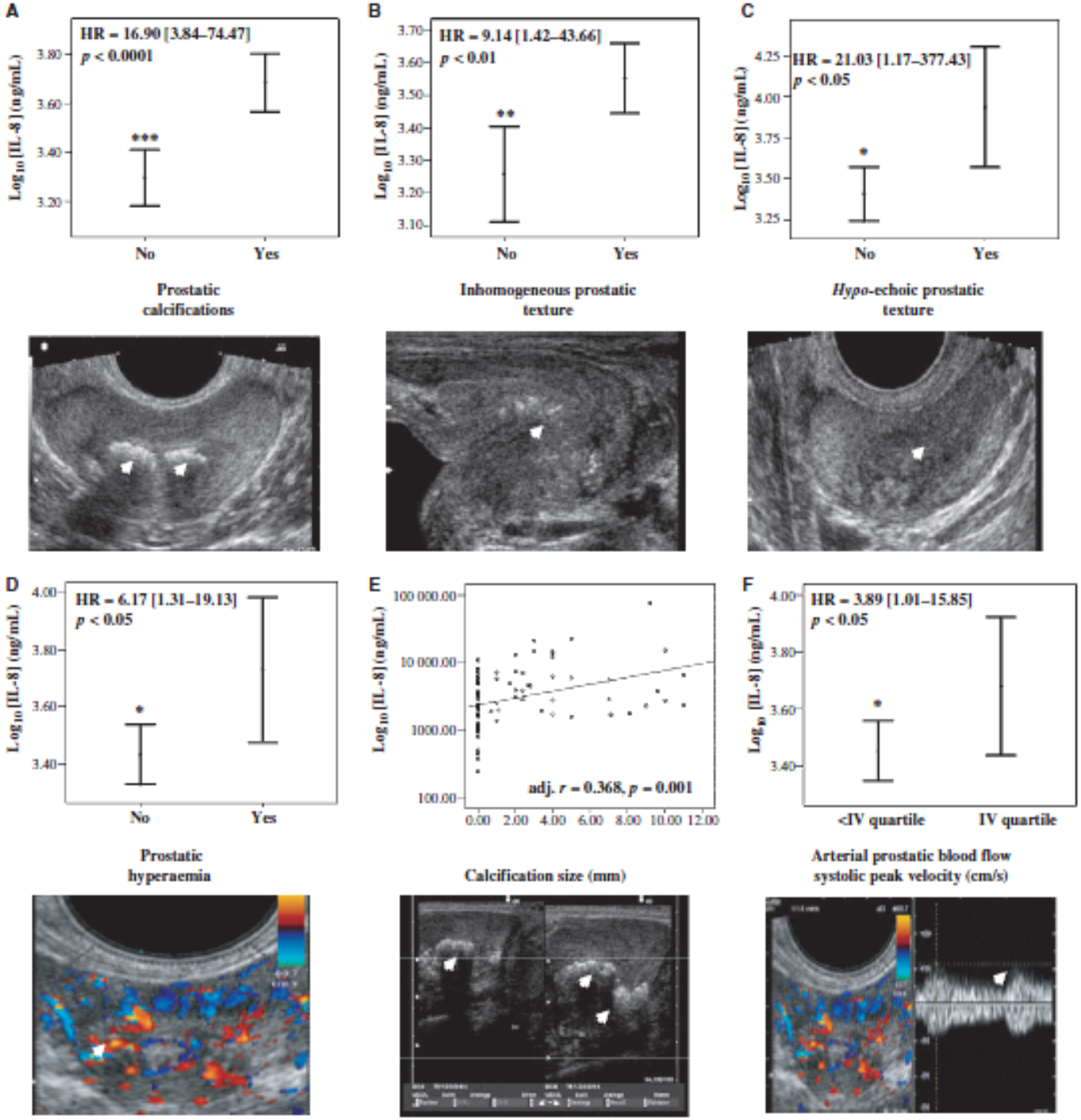
A
HR = 16.90 [3.84–74.47]
p < 0.0001
***
Log10 [IL-8] (ng/mL)
3.80
3.60
3.40
3.20
No
Yes
Prostatic calcifications
B
HR = 9.14 [1.42–43.66]
p < 0.01
**
3.70
3.60
3.50
3.40
3.30
3.20
3.10
Inhomogeneous prostatic texture
C
HR = 21.03 [1.17–377.43]
p < 0.05
*
4.25
4.00
3.75
3.50
3.25
Hypo-echoic prostatic texture
D
HR = 6.17 [1.31–19.13]
p < 0.05
*
4.00
3.80
3.60
3.40
Prostatic hyperaemia
E
100 000.00
10 000.00
1000.00
100.00
adj. r = 0.368, p = 0.001
0.00 2.00 4.00 6.00 8.00 10.00 12.00
Calcification size (mm)
F
HR = 3.89 [1.01–15.85]
p < 0.05
*
4.00
3.80
3.60
3.40
<IV quartile
IV quartile
Arterial prostatic blood flow systolic peak velocity (cm/s)

3.CDUS correlates of premature ejaculation (PE)

ORIGINAL RESEARCH—MEN'S SEXUAL HEALTH

Clinical Correlates of Erectile Dysfunction and Premature Ejaculation in Men with Couple Infertility

Francesco Lotti, MD,* Giovanni Corona, MD,*† Giulia Rastrelli, MD,* Gianni Forti, MD,* Emmanuele A. Jannini, MD,‡ and Mario Maggi, MD*

*Sexual Medicine and Andrology Unit, Department of Clinical Physiopathology, University of Florence, Florence, Italy; †Endocrinology Unit, Maggiore-Bellaria Hospital, Bologna, Italy; ‡Endocrinology and Medical Sexology, Experimental Medicine, University of L'Aquila, L'Aquila, Italy

J Sex Med 2012;9:2698–2707

The Association between Varicocele, Premature Ejaculation and Prostatitis Symptoms: Possible Mechanisms

Francesco Lotti, MD,* Giovanni Corona, MD,*,** Mario Mancini, MD,† Carlo Biagini, MD,‡ Giovanni M. Colpi, MD,† Selene Degli Innocenti, PhD,* Erminio Filimberti, PhD,* Mauro Gacci, MD,¶ Csilla Krausz, MD,* Alessandra Sforza, MD,** Gianni Forti, MD,* Edoardo Mannucci, MD,§ and Mario Maggi, MD*

*Andrology Unit, Department of Clinical Physiopathology, University of Florence, Florence, Italy; †Andrology and Urology Unit, San Paolo Hospital, Milan, Italy; ‡Alliance Medical SRL, Prato, Italy; ¶Department of Urology, University of Florence, Florence, Italy; §Diabetes Section Geriatric Unit, Department of Critical Care, University of Florence, Florence, Italy; **Endocrinology Unit, Maggiore-Bellaria Hospital, Bologna, Italy

J Sex Med 2009;6:2878–2887

Prostate inflammation is a well known cause of acquired PE

Premature ejaculation: old story, new insights

Emmanuele A. Jannini, M.D.,[a] Giacomo Ciocca, Ph.D.,[b] Erika Limoncin, Ph.D.,[b] Daniele Mollaioli, Ph.D.,[b] Stefania Di Sante, M.D.,[c] Daniele Gianfrilli, M.D., Ph.D.,[c] Francesco Lombardo, M.D.,[c] and Andrea Lenzi, M.D.[c]

Fertility and Sterility® Vol. 104, No. 5, November 2015

- **PE frequent in men with CP/CPPS**
- **CP frequent in men with PE**

* ORIGINAL RESEARCH—EJACULATORY DISORDERS

Antibiotic Treatment Can Delay Ejaculation in Patients with Premature Ejaculation and Chronic Bacterial Prostatitis

AbdelRahman El-Nashaar, MD,* and Rany Shamloul, MD†

J Sex Med 2007;4:491–496

* ORIGINAL RESEARCH—EJACULATORY DISORDERS

Clinical Parameters that Predict Successful Outcome in Men with Premature Ejaculation and Inflammatory Prostatitis

Wael Zohdy, MD

- **Antibiotic treatment of CP can delay ejaculation**

a.Premature ejaculation (PE) is associated with CDUS signs of prostate inflammation

ORIGINAL RESEARCH—MEN'S SEXUAL HEALTH

Clinical Correlates of Erectile Dysfunction and Premature Ejaculation in Men with Couple Infertility

Francesco Lotti, MD,* Giovanni Corona, MD,*† Giulia Rastrelli, MD,* Gianni Forti, MD,* Emmanuele A. Jannini, MD,‡ and Mario Maggi, MD*

*Sexual Medicine and Andrology Unit, Department of Clinical Physiopathology, University of Florence, Florence, Italy; †Endocrinology Unit, Maggiore-Bellaria Hospital, Bologna, Italy; ‡Endocrinology and Medical Sexology, Experimental Medicine, University of L'Aquila, L'Aquila, Italy

J Sex Med 2012;9:2698–2707

First demonstration of an association between CDUS signs and PE

Methods

- 244 men with couple infertility (WHO, 2000)

- Premature ejaculation diagnostic tool (PEDT)

PEDT score > 8: PE

EUROPEAN UROLOGY 52 (2007) 565–573

available at www.sciencedirect.com
journal homepage: www.europeanurology.com

European Association of Urology

Sexual Medicine

Development and Validation of a Premature Ejaculation Diagnostic Tool

Tara Symonds [a,], Michael A. Perelman [b], Stanley Althof [c], François Giuliano [d], Mona Martin [e], Kathryn May [a], Lucy Abraham [a], Anna Crossland [a], Mark Morris [a]*

✓. Premature Ejaculation Diagnostic Tool (PEDT) score

Prevalence PE (PEDT score > 8) ~ 16% : ~ 1 / 6 infertile men

Acquired: 62% **Lifelong: 38%**

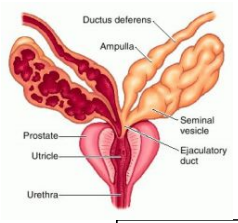

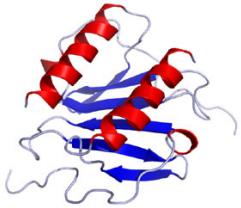

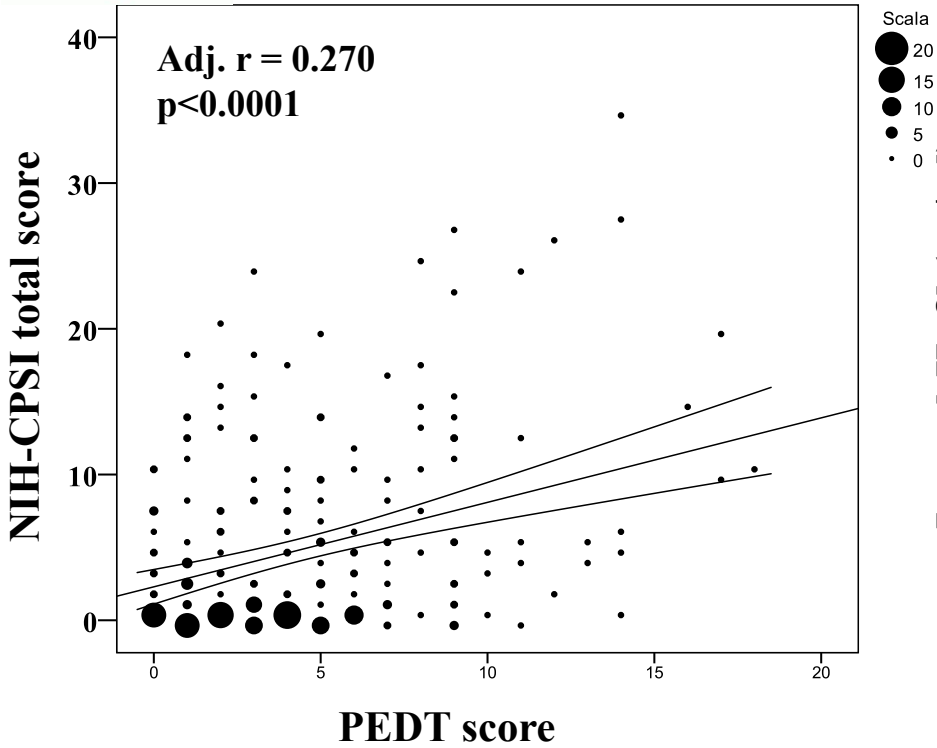

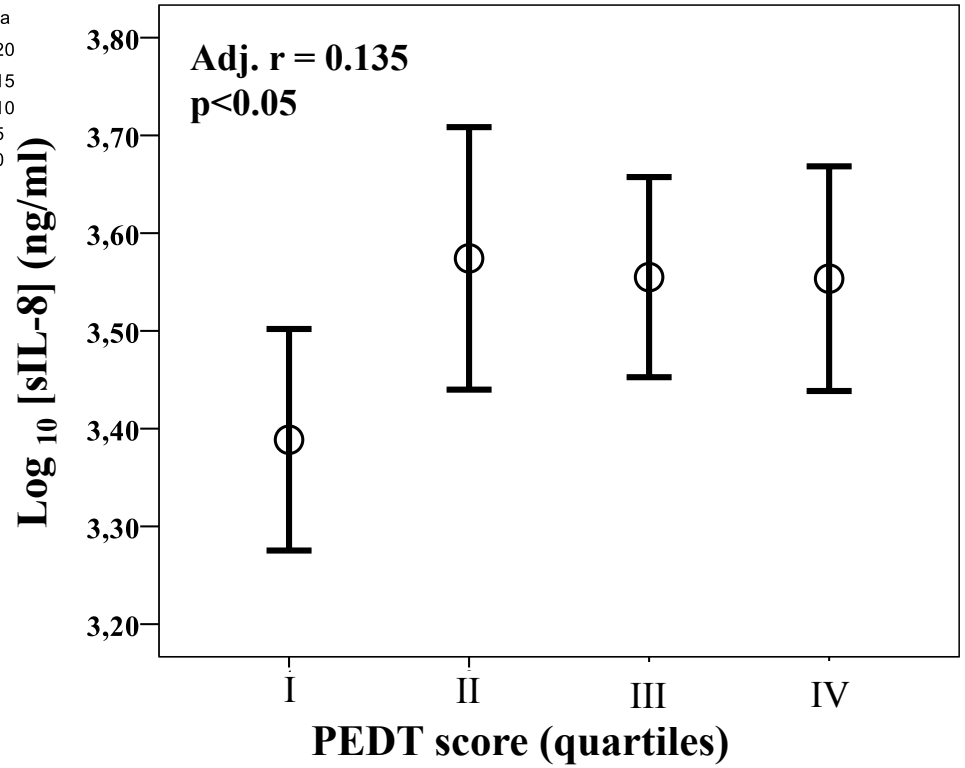

Adjusted for age

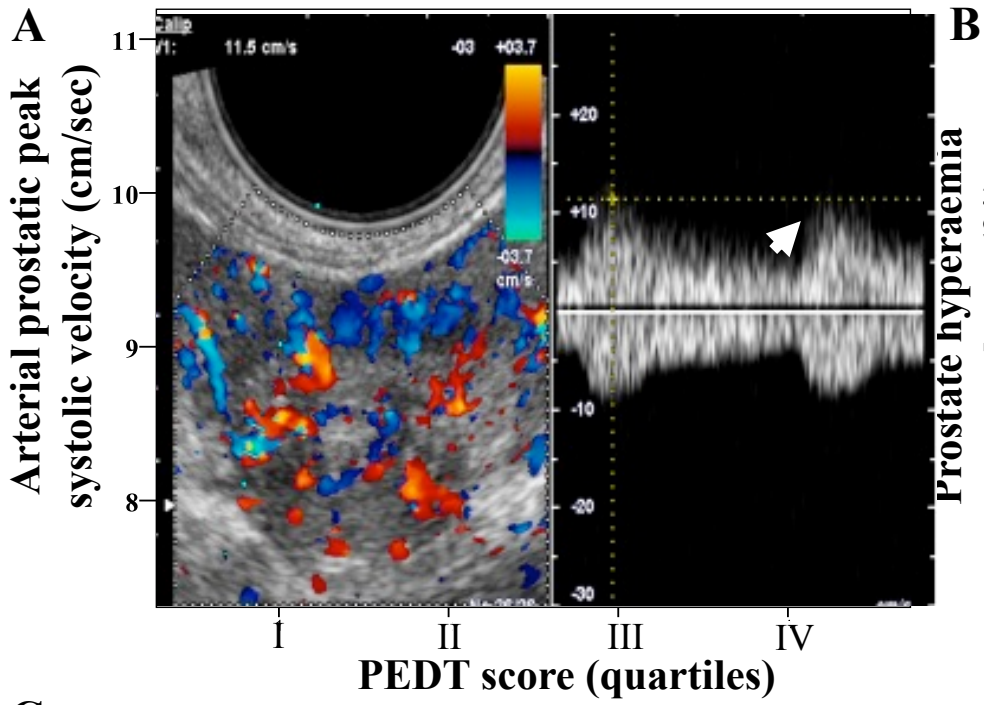

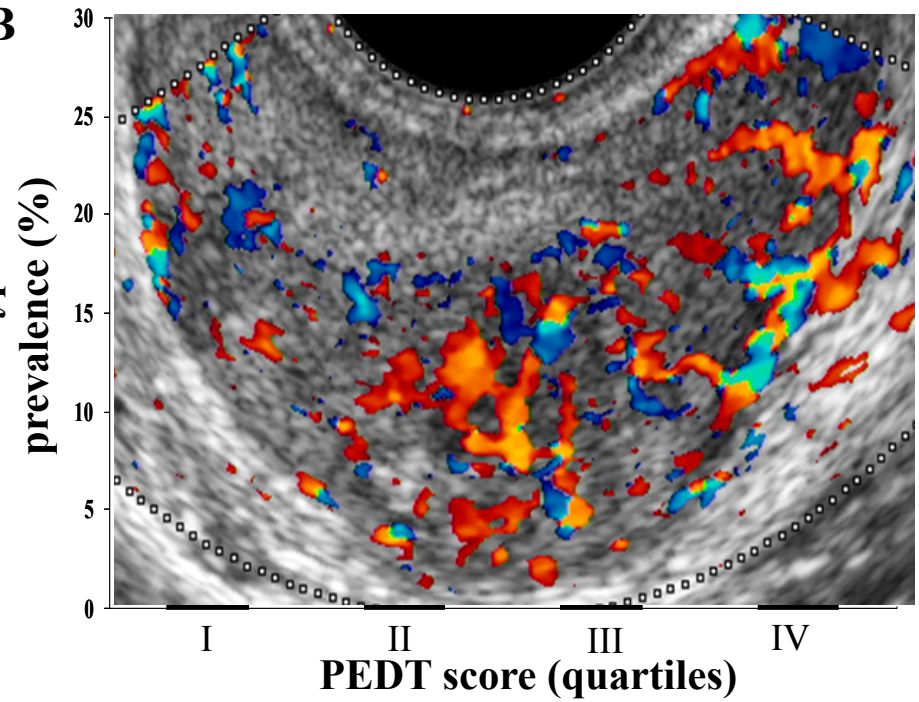

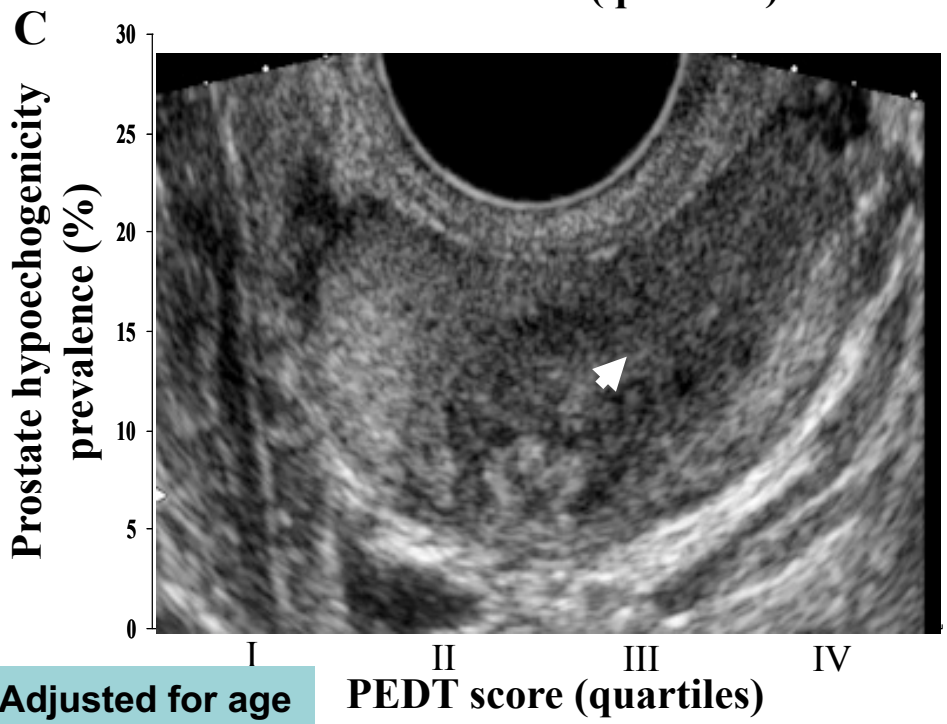

Adjusted for age

✓ **Results confirmed** comparing subjects with «**acquired» PE** (but not «lifelong») with subjects **with NO PE**

b.Varicocele is associated with CDUS signs of prostate inflammation and PE

The Association between Varicocele, Premature Ejaculation and Prostatitis Symptoms: Possible Mechanisms

Francesco Lotti, MD,* Giovanni Corona, MD,*,** Mario Mancini, MD,† Carlo Biagini, MD,‡ Giovanni M. Colpi, MD,† Selene Degli Innocenti, PhD,* Erminio Filimberti, PhD,* Mauro Gacci, MD,¶ Csilla Krausz, MD,* Alessandra Sforza, MD,** Gianni Forti, MD,* Edoardo Mannucci, MD,§ and Mario Maggi, MD*

*Andrology Unit, Department of Clinical Physiopathology, University of Florence, Florence, Italy; †Andrology and Urology Unit, San Paolo Hospital, Milan, Italy; ‡Alliance Medical SRL, Prato, Italy; ¶Department of Urology, University of Florence, Florence, Italy; §Diabetes Section Geriatric Unit, Department of Critical Care, University of Florence, Florence, Italy; **Endocrinology Unit, Maggiore-Bellaria Hospital, Bologna, Italy

J Sex Med 2009;6:2878–2887

2 cohorts

1. Clinical study on 2448 men with sexual dysfunction

2.CDUS study on 139 men with couple infertility

Study 1. Prevalence of premature ejaculation (PE) in 2448 subjects

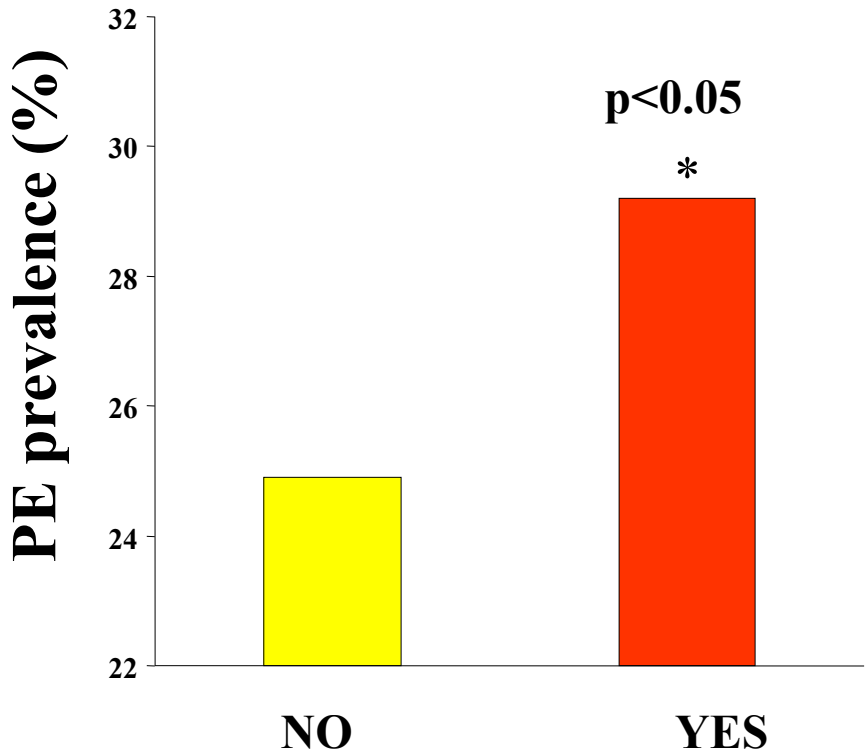

Any degree of varicocele

Adjusted for:
- **patient's age**
- **partner's age**

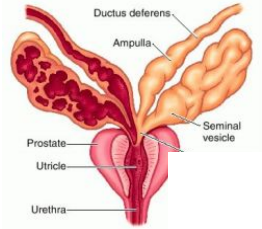

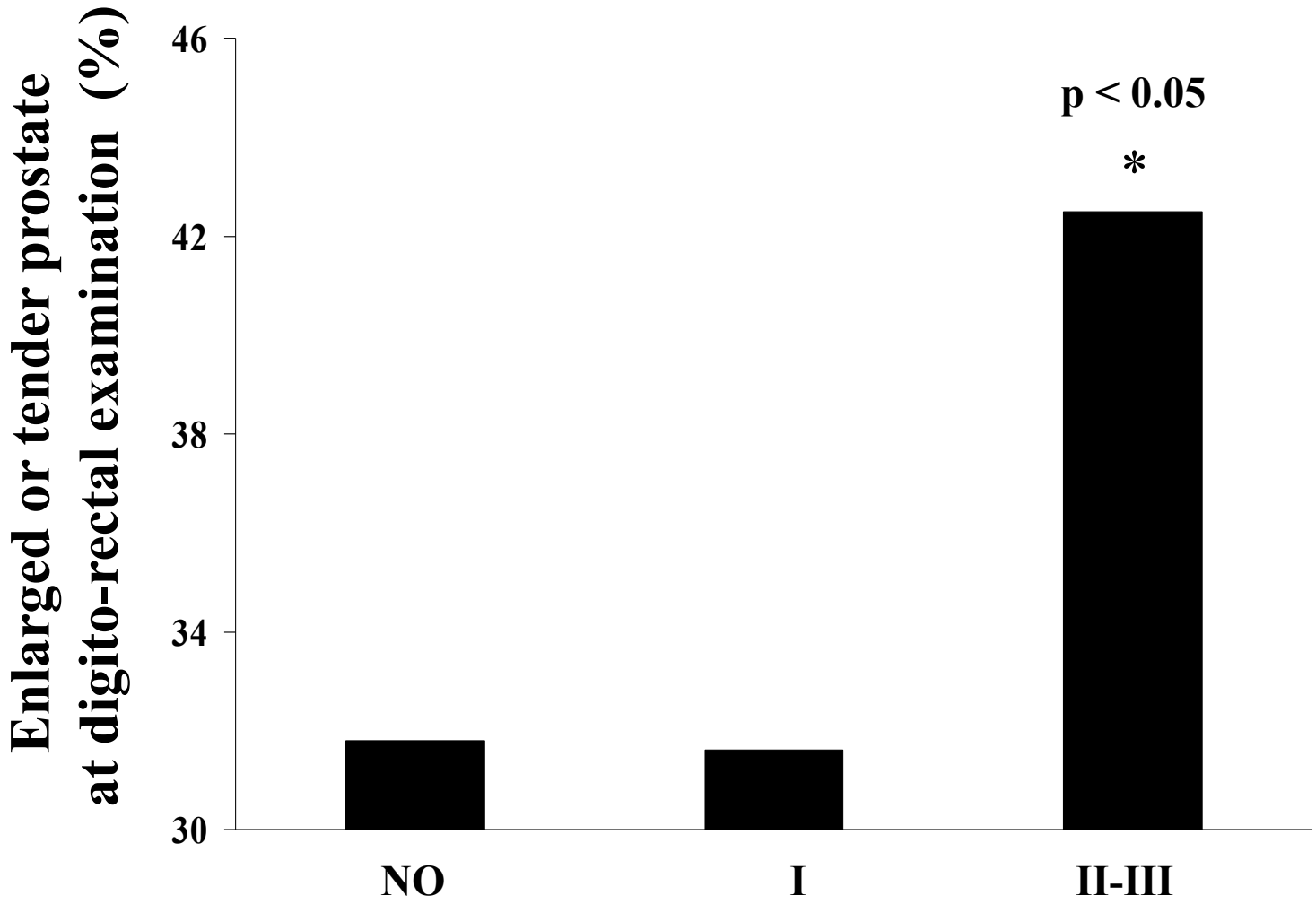

Adjusted for:
- **patient's age**

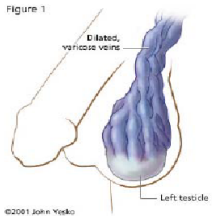

Study 2: 139 males of infertile couples

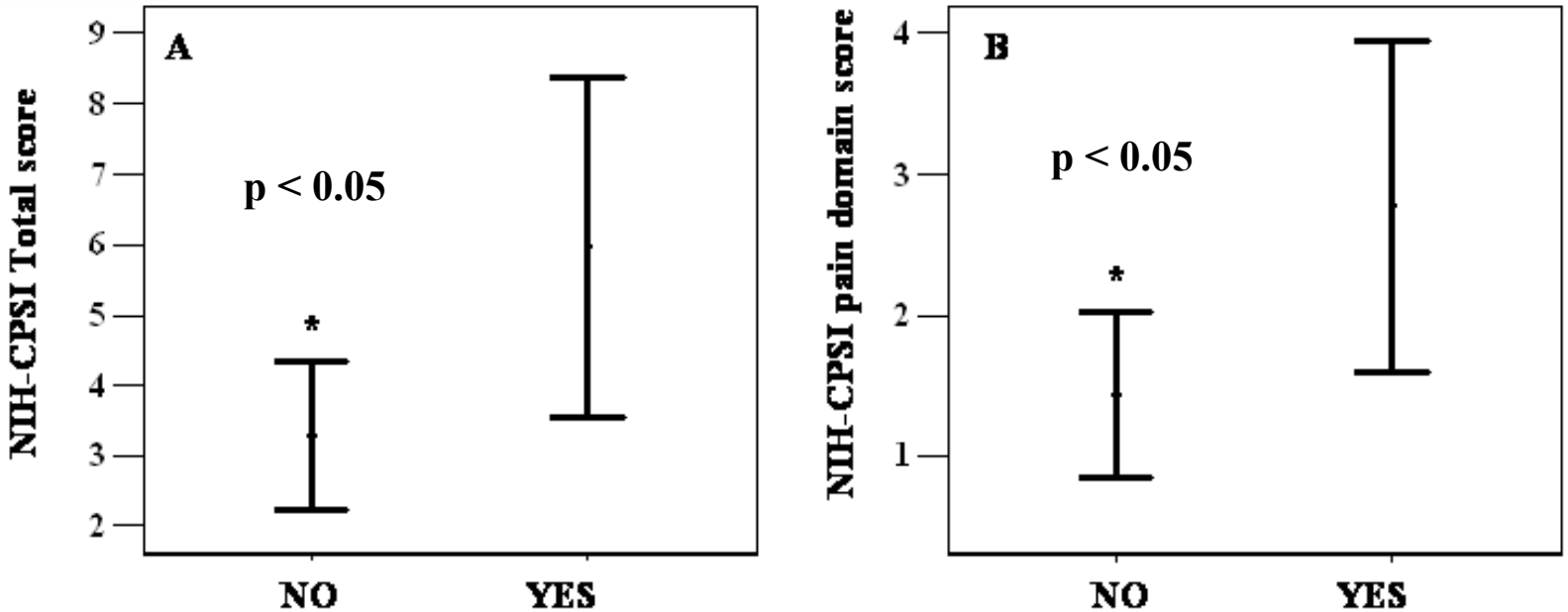

Severe ultrasound varicocele

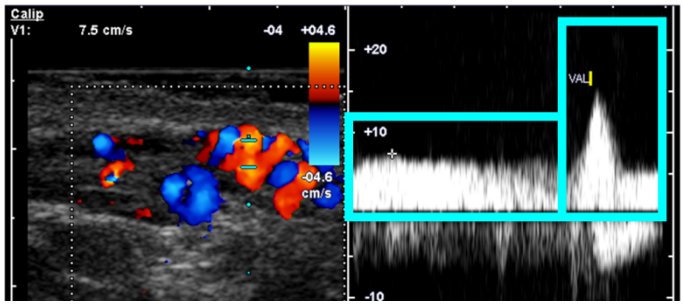

Lotti et al., J Sex Med, 2009

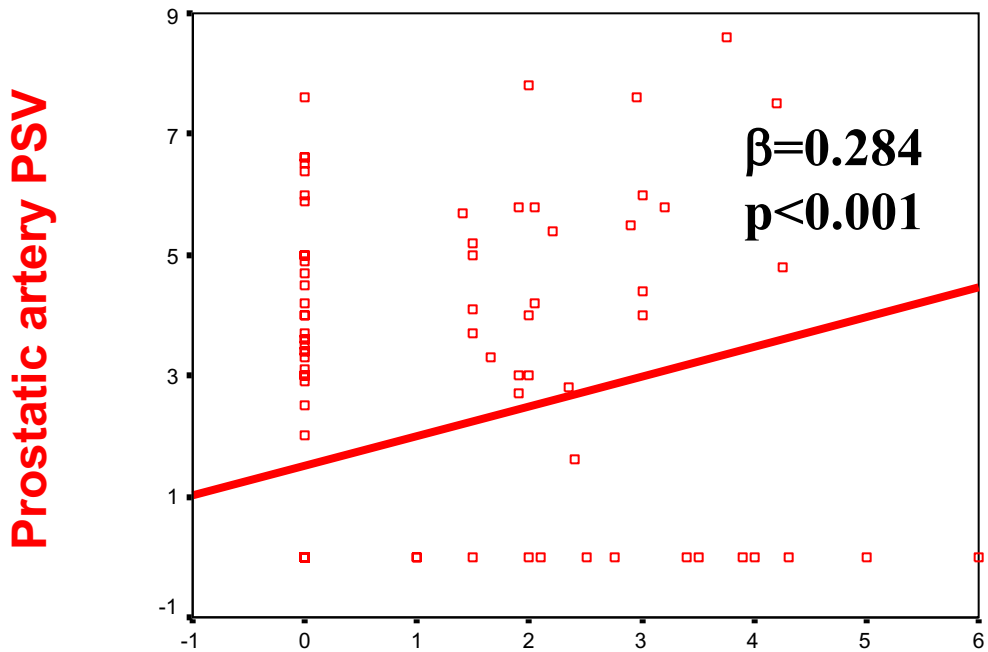

Venous reflux velocity
spermatic internal vein

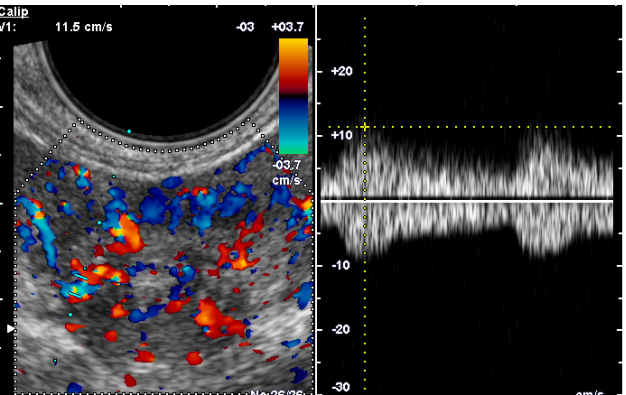

Lotti et al., J Sex Med, 2009

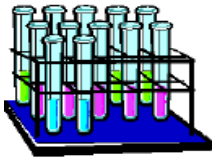

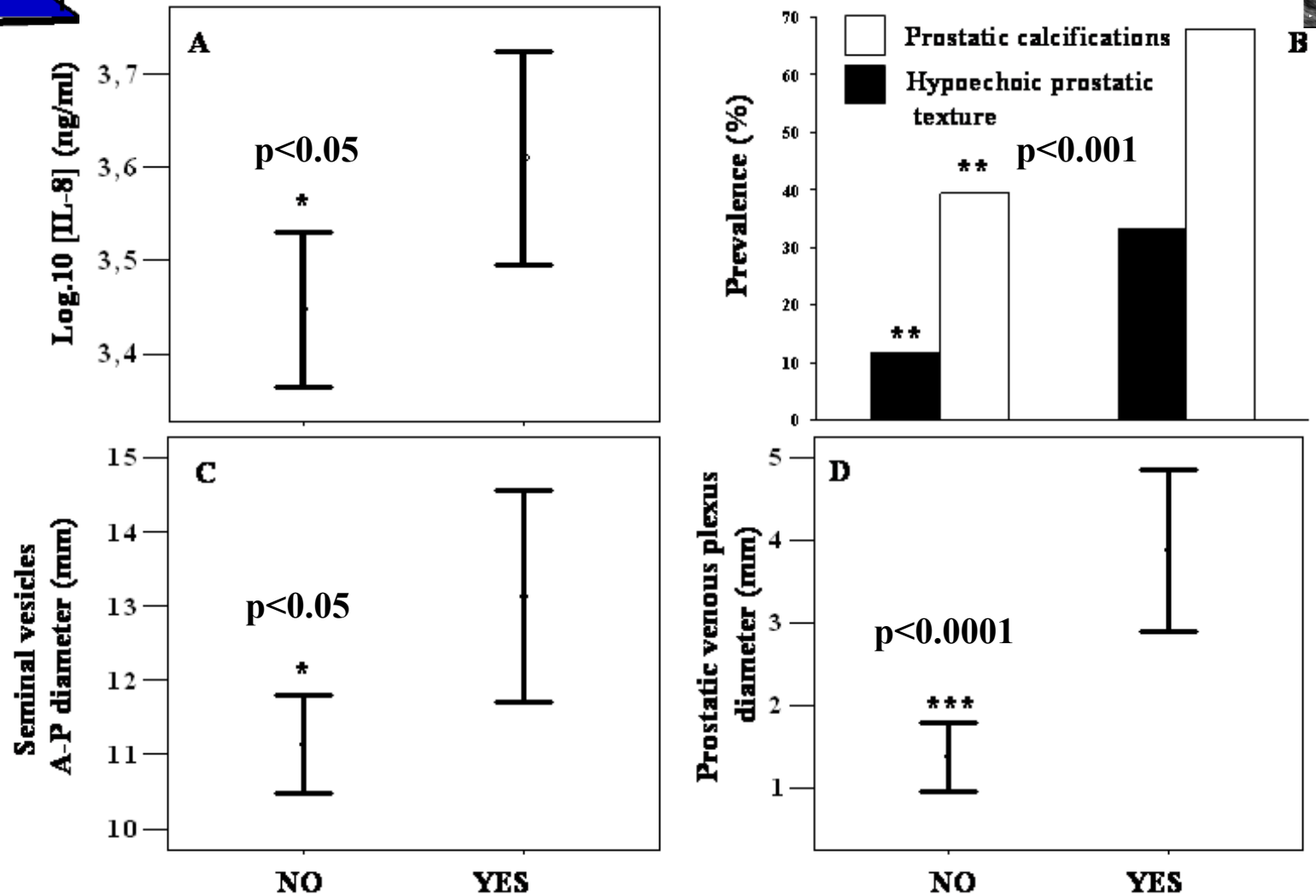

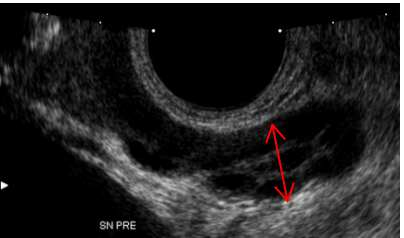

Severe ultrasound varicocele

*p<0.05, **p<0.001, ***p<0.0001

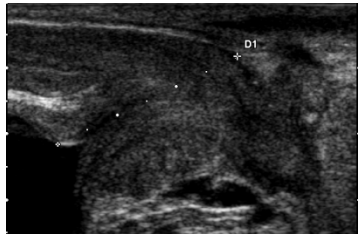

Physiopathologic mechanism linking varicocele, prostatite inflammation and PE?

Il varicocele is associated with venous abnormalities…

Puigvert A. Point of view: prostatoanal syndrome. Urology 1975;4:930-1

Pavone et al. Correlation between chronic prostatitis syndrome and pelvic venous disease: a survey of 2554 urologic outpatients. Eur Urol. 2000; 37: 400-3

Callam MJ. Epidemiology of varicose veins. Br J Urol 1994;81:167-173.

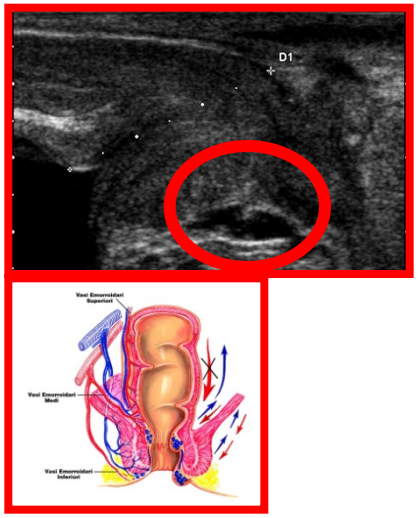

…in particular with higher diameter of the prostatic venous plexus

Is Varicocele Associated With Underlying Venous Abnormalities? Varicocele and the Prostatic Venous Plexus

Hideo Sakamoto* and Yoshio Ogawa
From the Department of Urology, Showa University School of Medicine, Tokyo, Japan

J Urol. 2008;180:1427-31

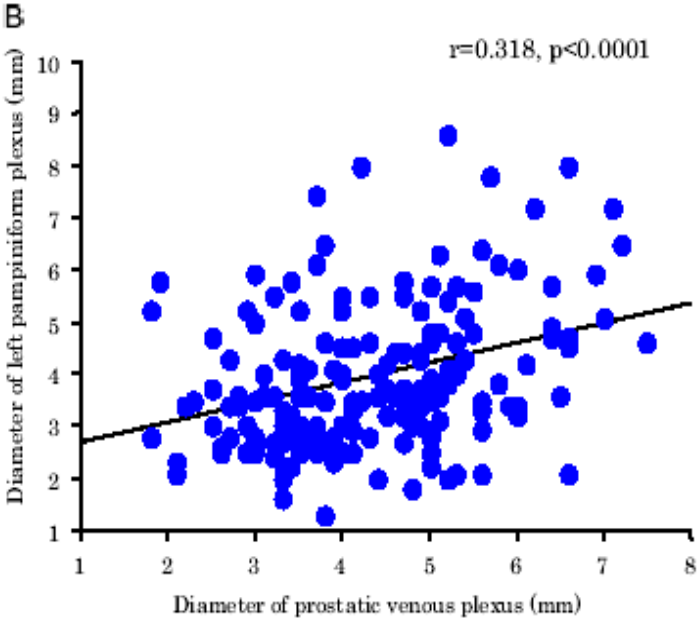

First International Journal of Andrology
ANDROLOGIA

ORIGINAL ARTICLE

Reversal of benign prostate hyperplasia by selective occlusion of impaired venous drainage in the male reproductive system: novel mechanism, new treatment

Y. Gat[1,2], M. Gornish[1], M. Heiblum[2] & S. Joshua[3]

1 Andrology and Interventional Radiology Unit, Maayanei HaYeshua Medical Centre, Bnei Brak, Israel;
2 Braun Center for Sub Micron Research, Department of Condensed Matter Physics, Weizmann Institute of Science, Rehovot, Israel;
3 Department of Chemistry, Technion, Israel Institute of Technology, Haifa, Israel

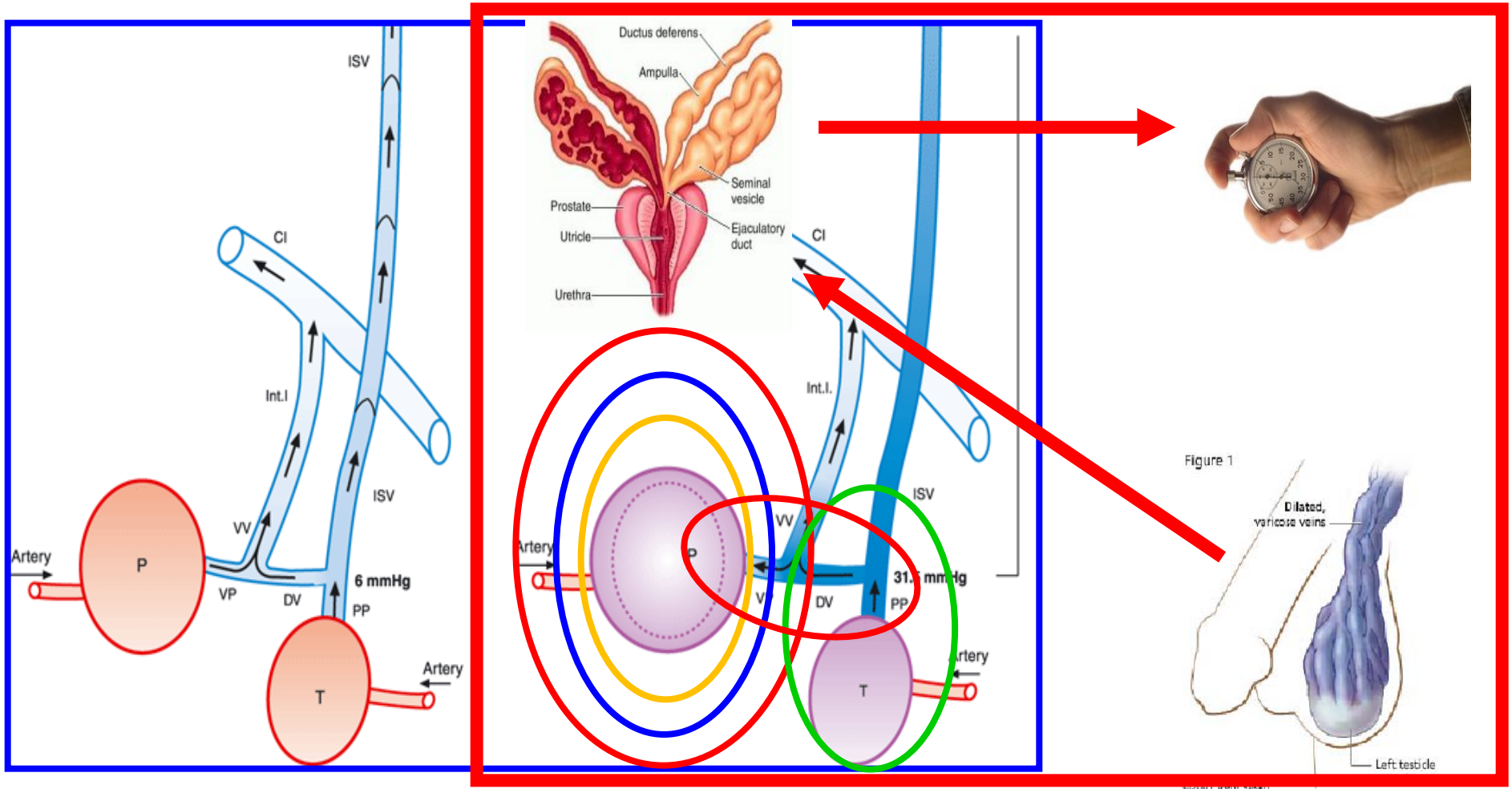

First International Journal of Andrology
andrologia

ORIGINAL ARTICLE

Impact of varicocelectomy on premature ejaculation in varicocele patients

A.-F. Ahmed[1,2], A.-S. Abdel-Aziz[3,4], A.M. Maarouf[5,6], M. Ali[1,7], A.-A. Emara[1,8] & A. Gomaa[1,9]

© 2014 Blackwell Verlag GmbH
Andrologia 2014, **xx**, 1–6

We concluded that varicocelectomy is clearly related to improvement of premature ejaculation and testicular hormonal function in varicocele patients.

Table 1 The base line characteristics of studied patients

	Group I (varicocelectomy group) (n = 73)	Group II (control group) (n = 56)	P-value
Age	30.71 ± 7.39	31.39 ± 6.98	0.596
Varicocele			0.315
LT side varicocele	39 (53.4)	24 (42.9)	
Grade 1	8	6	
Grade 2	20	12	
Grade 3	11	6	
Bilateral varicocele	34 (46.6)	32 (57.1)	
RT side			
Grade 1	13	12	
Grade 2	15	13	
Grade 3	6	7	
LT side			
Grade 1	5	4	
Grade 2	20	24	
Grade 3	9	6	
PEDT	15.56 ± 2.50	15.89 ± 2.41	0.451
IIEF-5	23.27 ± 1.23	23.39 ± 1.11	0.571
Serum TT, ng ml^{-1}	331.89 ± 56.85	341.87 ± 58.92	0.332
Testicular size, cc	9.94 ± 2.59	10.14 ± 2.22	0.642
ISV diameter, mm	3.36 ± 0.47	3.23 ± 58	0.158

Table 2 The mean IIEF-5 and PEDT scores at base line and end of study in both groups

	Group I (varicocelectomy group) (n = 73)				Group II (control group) (n = 56)			
	Baseline	At end of study	% change	P-value	Baseline	At end of study	% change	P-value
PEDT	15.56 ± 2.50	11.37 ± 4.25	−26.93	<0.001	15.89 ± 2.41	16.21 ± 1.85	+2.01	0.159
Serum TT, ng ml^{-1}	331.89 ± 56.85	357.97 ± 53.14	+7.86	<0.001	341.87 ± 58.92	335.25 ± 57.11	−1.94	0.055
IIEF-5	23.27 ± 1.23	23.41 ± 1.08	+0.60	0.040	23.39 ± 1.11	23.13 ± 1.25	−1.11	0.079
Testicular size, cc	9.94 ± 2.59	10.15 ± 2.47	+2.11	0.054	10.14 ± 2.22	9.64 ± 1.96	−4.93	0.001

Seminal vesicles

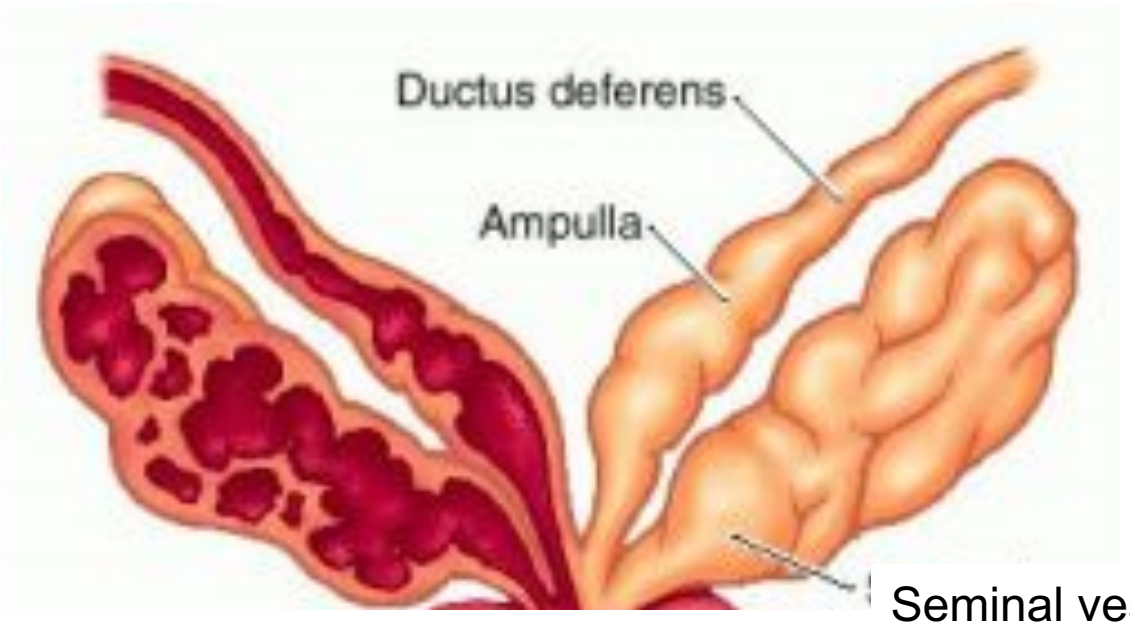

Seminal vesicle

Seminal vesicles

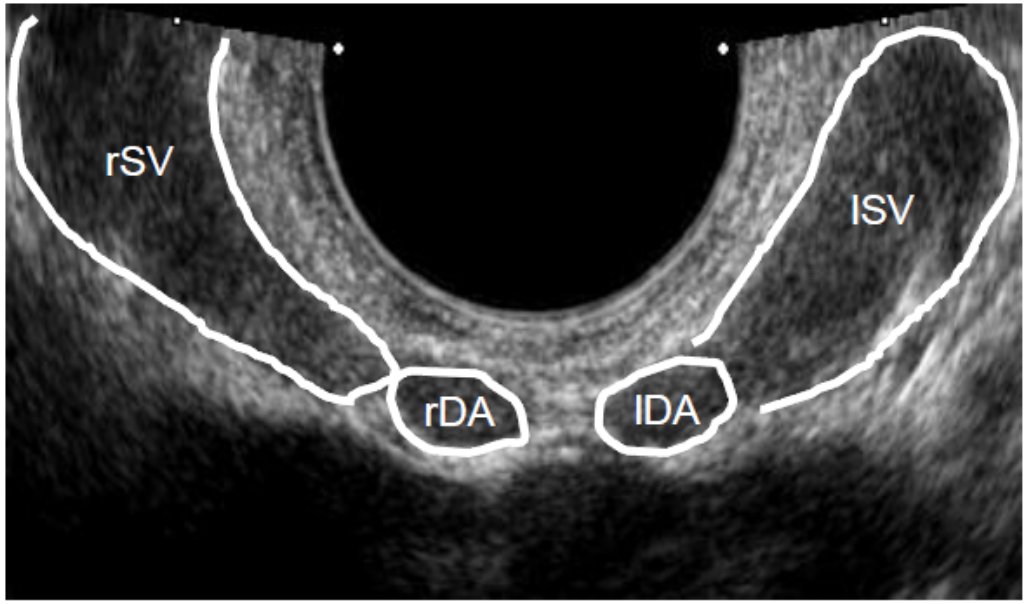

Transversal scan

SV; seminal vesicles
DA: deferentia ampulla
r: right
l:left

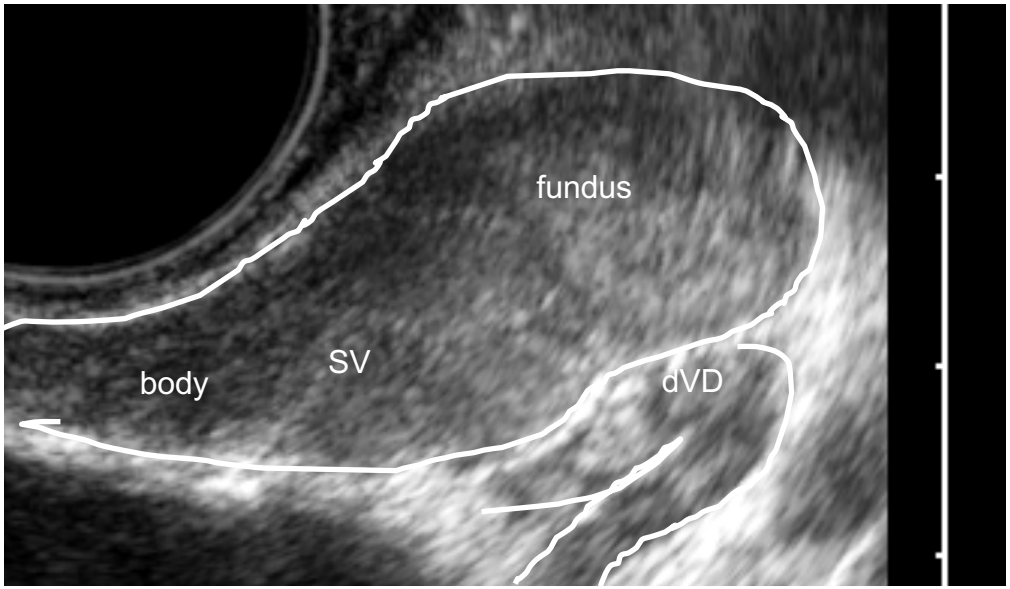

Longitudinal scan

VD: vas deferens

Human Reproduction Update, Vol.0, No.0 pp. 1–28, 2014
doi:10.1093/humupd/dmu042
human reproduction update

Ultrasound of the male genital tract in relation to male reproductive health

Francesco Lotti and Mario Maggi*
Sexual Medicine and Andrology Unit, Department of Experimental and Clinical Biomedical Sciences, University of Florence, Florence, Italy

Seminal vesicles inflammation

Asimmetry

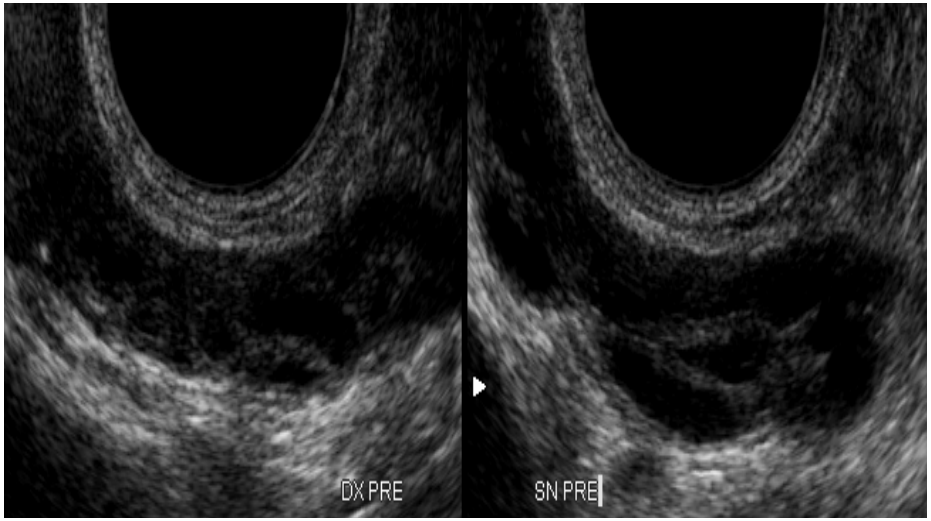

Wall thickening and septa

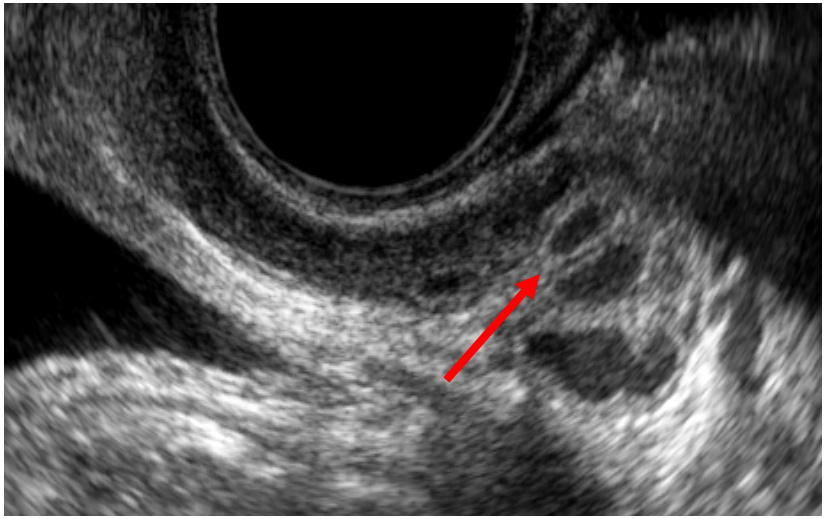

Calcifications

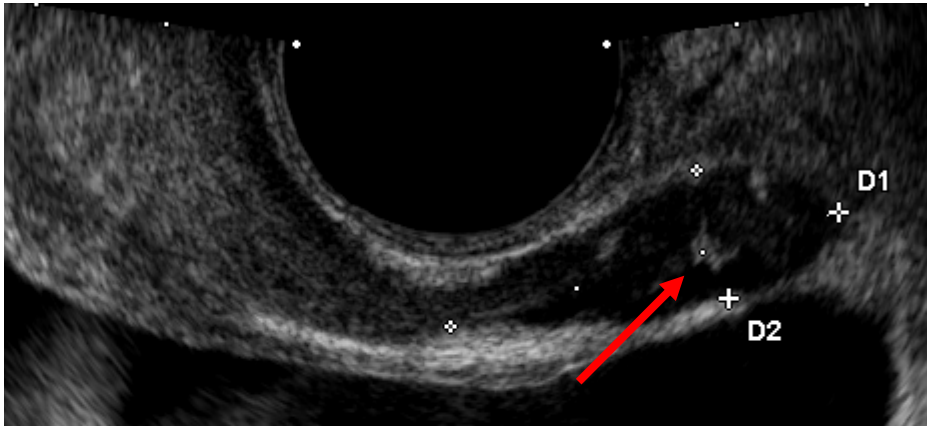

Human Reproduction vol.14 no.8 pp.2025–2030, 1999

Seminal leukocyte concentration and related specific reactive oxygen species production in patients with male accessory gland infections

E.Vicari

Areas of endocapsulation

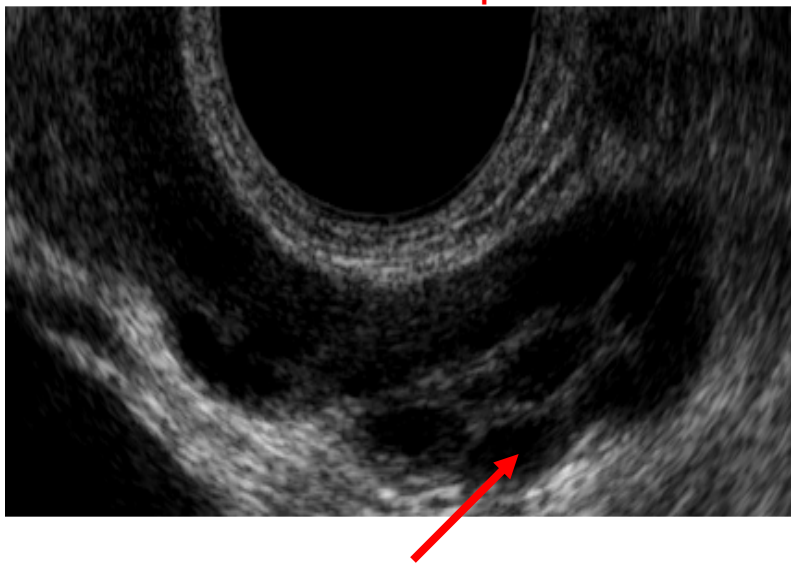

Criticisms

- Asimmetry: no cut-off

Human Reproduction, Vol.27, No.4 pp. 974–982, 2012
Advanced Access publication on February 16, 2012 doi:10.1093/humrep/des032

human reproduction ORIGINAL ARTICLE *Andrology*

Seminal vesicles ultrasound features in a cohort of infertility patients

F. Lotti[1], G. Corona[1,2], G.M. Colpi[3], E. Filimberti[1], S. Degli Innocenti[1], M. Mancini[3], E. Baldi[1], I. Noci[4], G. Forti[1], and M. Maggi[1,*]

- Areas of endocapsulation:

-reduction after ejaculation
(do not assess before ejaculation to avoid overestimation of MAGI)
-also signs of stasis/subosbtruction

- Mainly signs of past infections/chronic inflammation

- No available CDUS signs of current inflammation
  (no studies on vascularization)

International Journal of Andrology
international journal of andrology ISSN 0105-6263

ORIGINAL ARTICLE

Ultrasonographic and clinical correlates of seminal plasma interleukin-8 levels in patients attending an andrology clinic for infertility

F. Lotti,*[1] G. Corona,*†[1] M. Mancini,‡ E. Filimberti,* S. Degli Innocenti,* G. M. Colpi,‡ E. Baldi,* I. Noci,§ G. Forti,* L. Adorini¶ and M. Maggi*

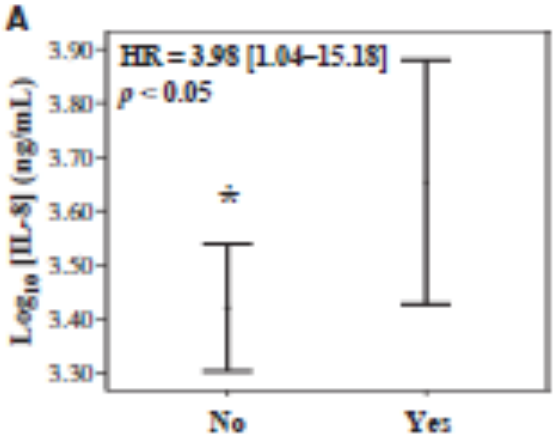

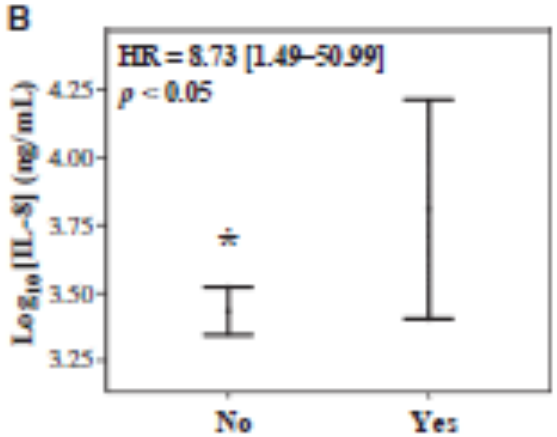

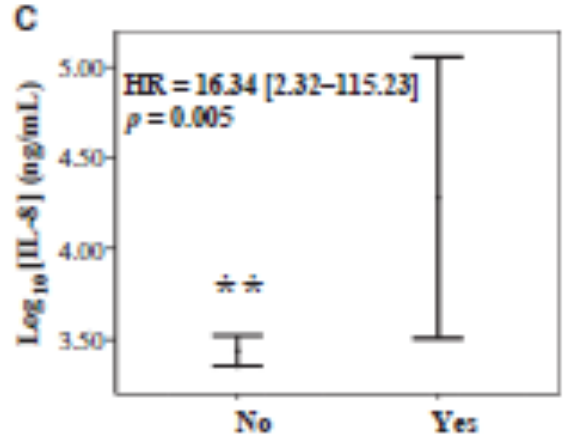

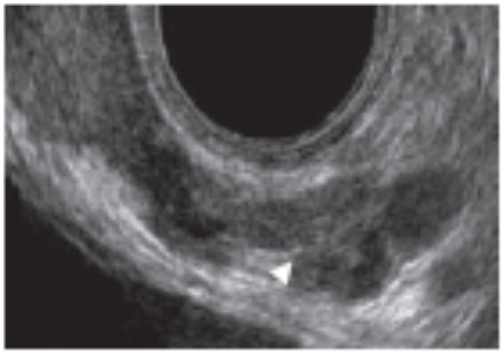

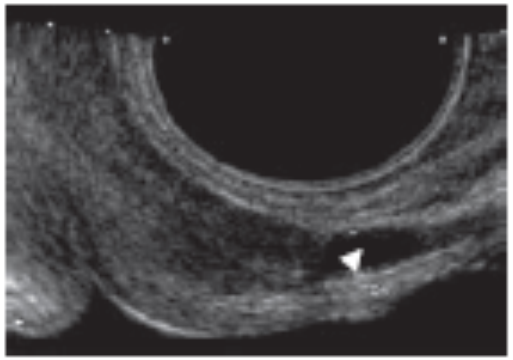

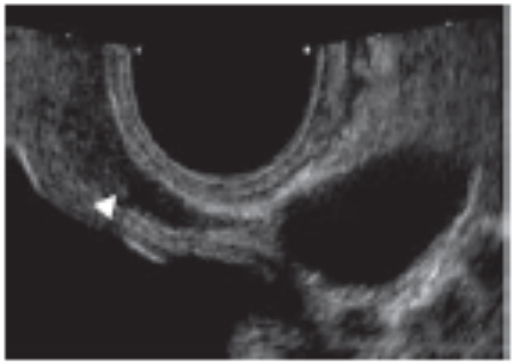

Epididymis

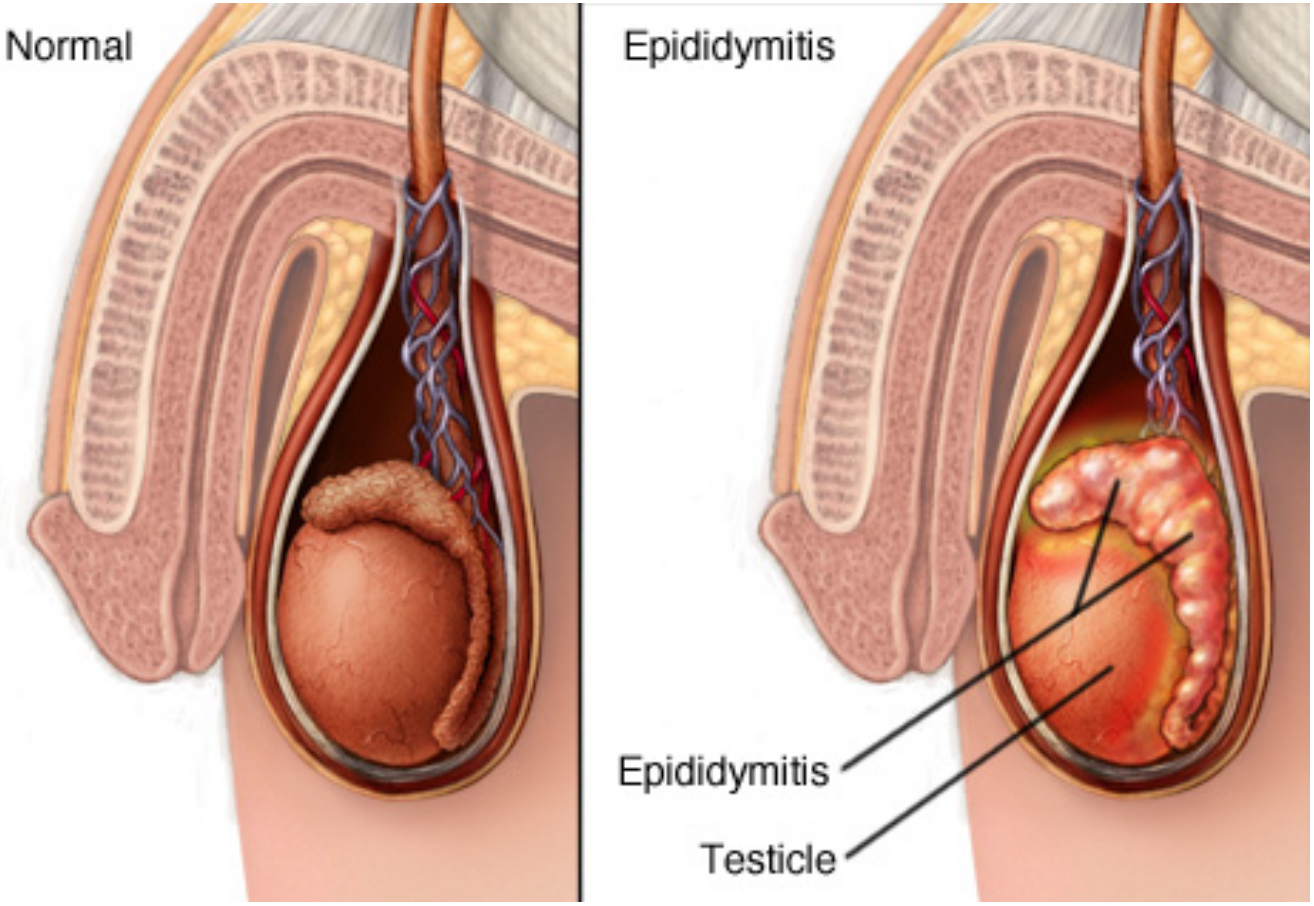

Epididymal inflammation

Dilated head (> 12 mm) or tail (> 6 mm)

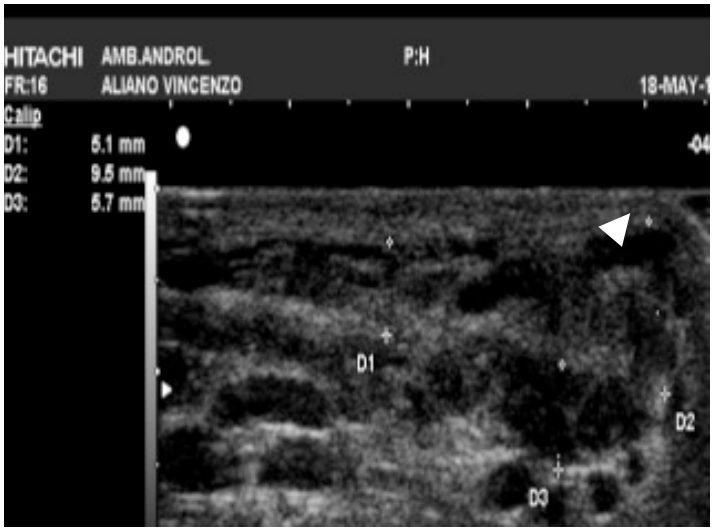

Hypoechoic (oedema; acute)

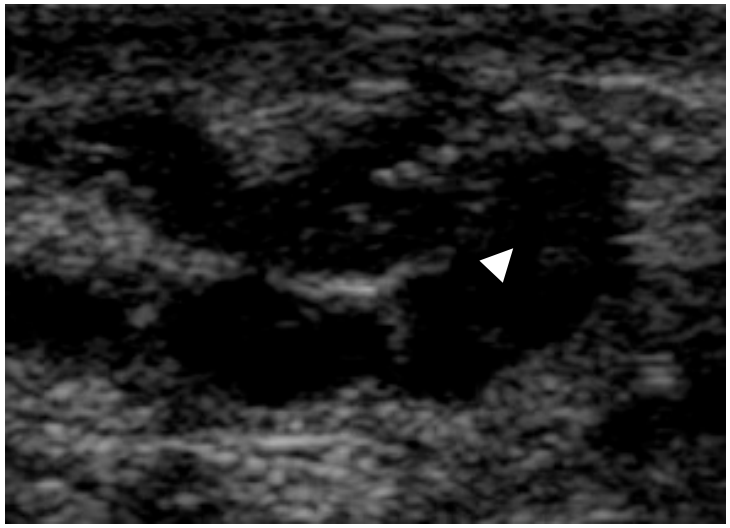

Hyperechoic (chronic)

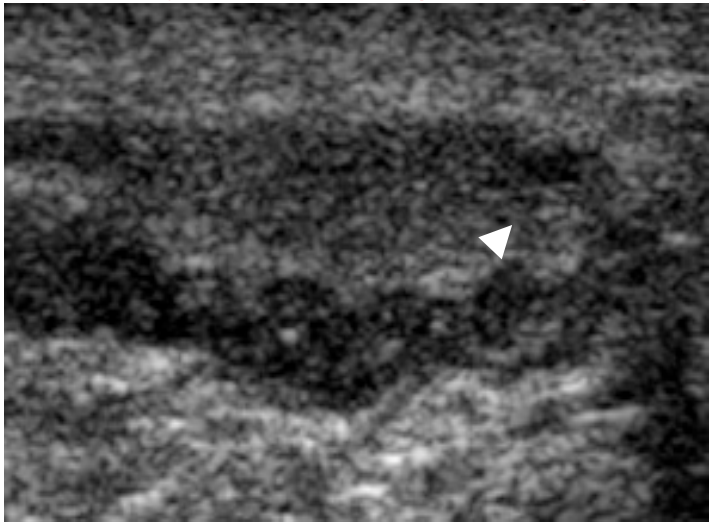

Hydrocele

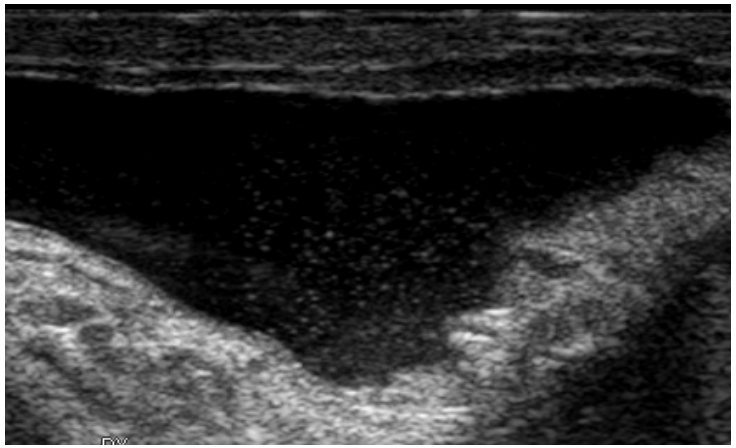

Human Reproduction vol.14 no.8 pp.2025–2030, 1999

Seminal leukocyte concentration and related specific reactive oxygen species production in patients with male accessory gland infections

E.Vicari

Criticisms

- **Hypoechoic and Hyperechoic:**
qualitative parameters, not standardized

- **Hydrocele:**
-common also in healthy men;
-no volume cut-off

- **Mainly signs of past infections/chronic inflammation**

- **The only available CDUS sign of current inflammation is qualitative: hyperemia → key role in diagnosis (no arterial PSV cut-off)**

Acute epididymitis

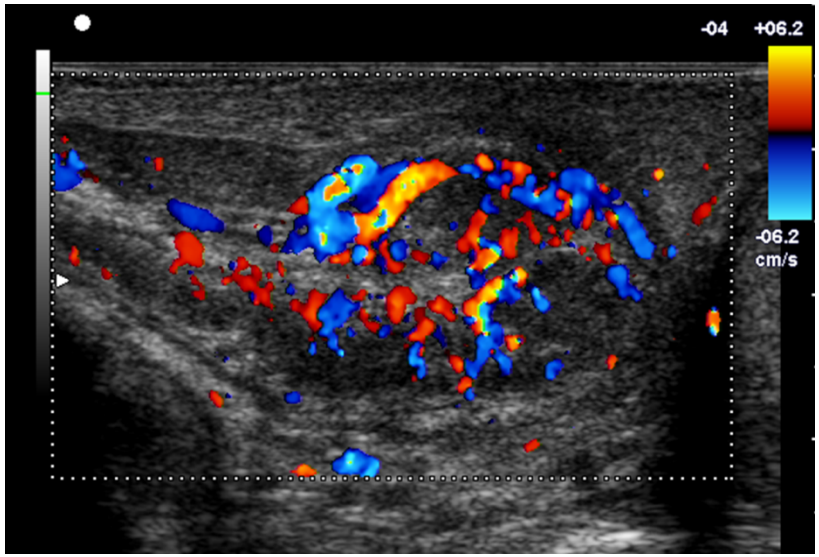

Pain, fever
Concomitant orchitis: 37-47%

CDUS: *enhanced vascularization*
diffuse enlargement, inhomogeneous hypoechoic echo-texture, hydrocele

After treatment: normalization

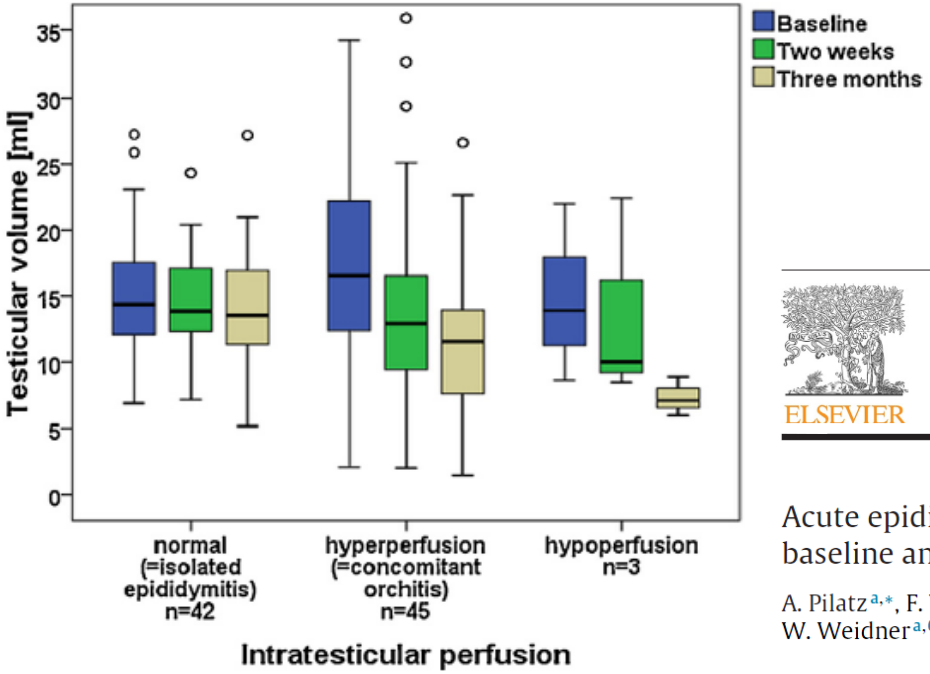

European Journal of Radiology xxx (2013) xxx–xxx

Contents lists available at ScienceDirect

European Journal of Radiology

journal homepage: www.elsevier.com/locate/ejrad

Acute epididymitis in ultrasound: Results of a prospective study with baseline and follow-up investigations in 134 patients

A. Pilatz[a,*], F. Wagenlehner[a,1], T. Bschleipfer[a,2], H.-C. Schuppe[a,3], T. Diemer[a,4], T. Linn[b,5], W. Weidner[a,6], B. Altinkilic[a,7]

Chronic epididymitis

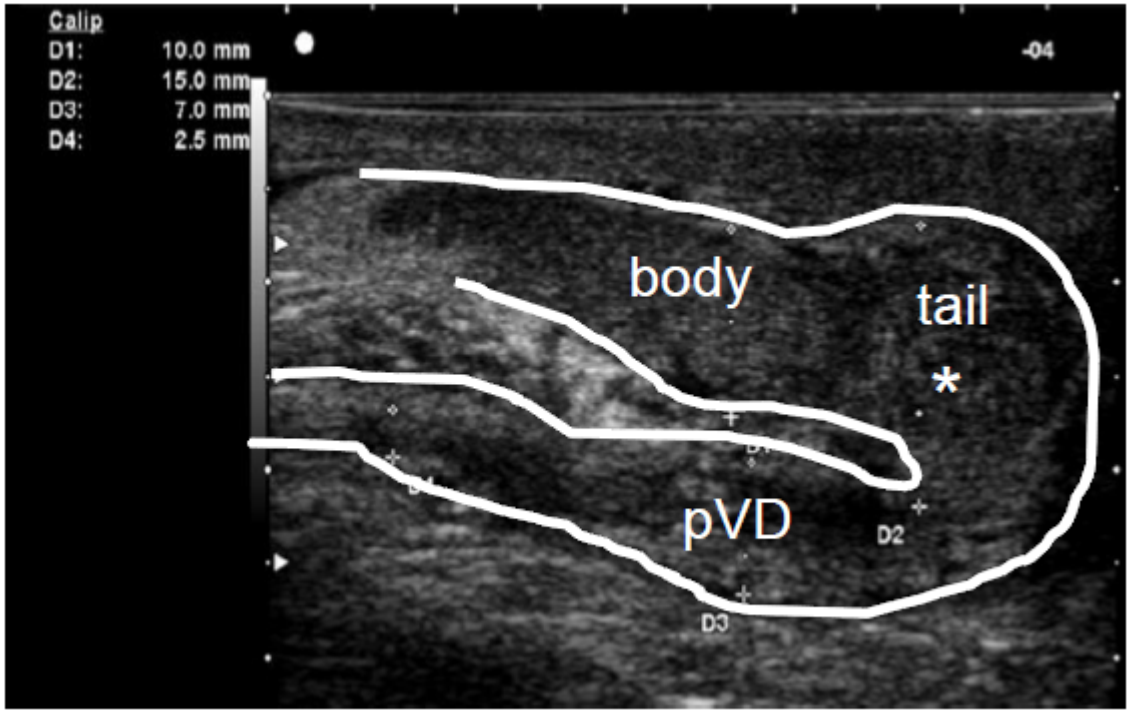

++ tail

Enlargement

Hyperechogenicity

Reduced sperm motility and morphology

First International Journal of Andrology
ANDROLOGIA

Chronic epididymitis: impact on semen parameters and therapeutic options

G. Haidl[1], J. P. Allam[1] & H.-C. Schuppe[2]

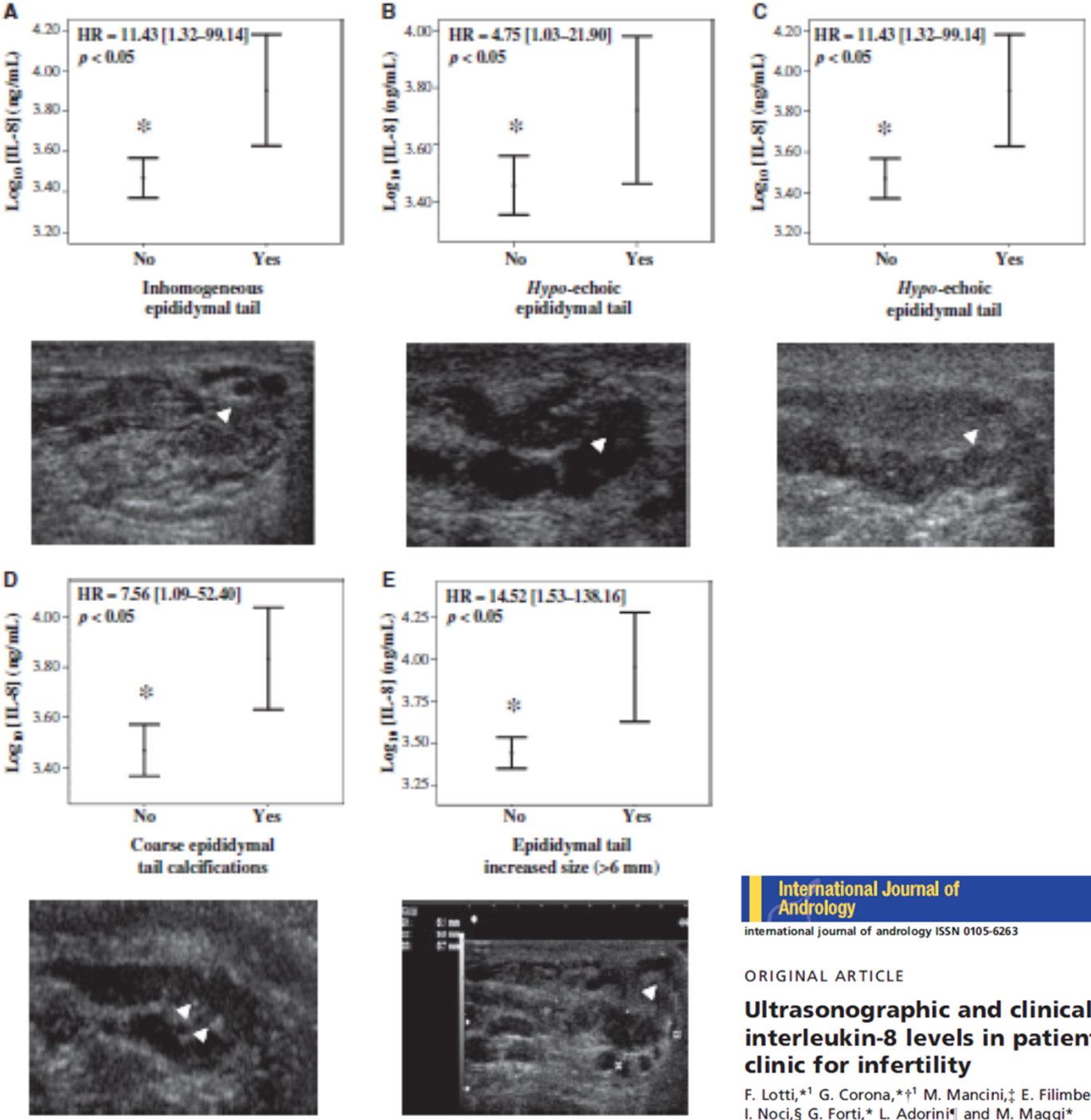

International Journal of Andrology

international journal of andrology ISSN 0105-6263

ORIGINAL ARTICLE

Ultrasonographic and clinical correlates of seminal plasma interleukin-8 levels in patients attending an andrology clinic for infertility

F. Lotti,*[1] G. Corona,*†[1] M. Mancini,‡ E. Filimberti,* S. Degli Innocenti,* G. M. Colpi,‡ E. Baldi,* I. Noci,§ G. Forti,* L. Adorini¶ and M. Maggi*

Human Reproduction Update, Vol.0, No.0 pp. 1–28, 2014
doi:10.1093/humupd/dmu042

human
reproduction
update

Ultrasound of the male genital tract in relation to male reproductive health

Francesco Lotti and Mario Maggi*

Sexual Medicine and Andrology Unit, Department of Experimental and Clinical Biomedical Sciences, University of Florence, Florence, Italy

However, sonographic imaging of MGT still suffers from a lack of standardization and often tends to produce subjective and vague diagnoses. This is the main reason why the European Academy of Andrology has promoted an ongoing multicenter study (see at http://www.andrologyacademy.net/studies.php) aimed at defining the anatomic and functional characteristic of healthy, fertile men, i.e. those who are fathering or have fathered in the past year. Defining US parameters of male fertility will be of great help in establishing criteria for their pathological counterparts in subfertility/infertility.

EAA Multicentre Study

«Standardization of the male genital tract colour-Doppler ultrasound in healthy, fertile men*»

*Healthy partners of a pregnant women in the second or third trimesters of pregnancy or men who fathered a child during the last one year

Welcome | About Us | News | Membership | Examinations | Grants | Education | Journals | EAA Studies | Library

More details

Ultrasound

Standardization of the male genital tract colour-Doppler ultrasound parameters in healthy, fertile men

EAA Multicentre Studies

Under the Patronage of the European Academy of Andrology (EAA)

Standardization of the male genital tract colour-Doppler ultrasound parameters in healthy, fertile men

PubMed citation

- Overview
- Overview: July 2015 update
- Appendix A-Interview, male medical history and physical examination
- Appendix B- Standardized procedures to evaluate male genital tract by ultrasound
- Appendix B - figures
- Appendix C - Standardization ultrasound parameters BEFORE ejaculation
- Appendix C - Standardization ultrasound parameters AFTER ejaculation
- Appendix D - Florence Informed Consent
- Appendix E - Florence IRB and AOUC approval

EAA Centers

- Ancona, Italy (Prof Balercia)
- Barcelona, Spain (Prof Rajmil)
- Cairo, Egypt (Prof. Shaeer)
- Catania, Italy (Prof Calogero)
- Florence, Italy (Prof Maggi, Dr Lotti) (Coordinator Center)
- Giessen, Germany (Prof Weidner)
- Halle-Saale, Germany (Prof Behre)
- L'Aquila, Italy (Prof Francavilla)
- Muenster, Germany (Prof Kliesch)
- Rome, Italy (Prof Lenzi, Prof Isidori)
- Tartu, Estonia (Prof Punab)

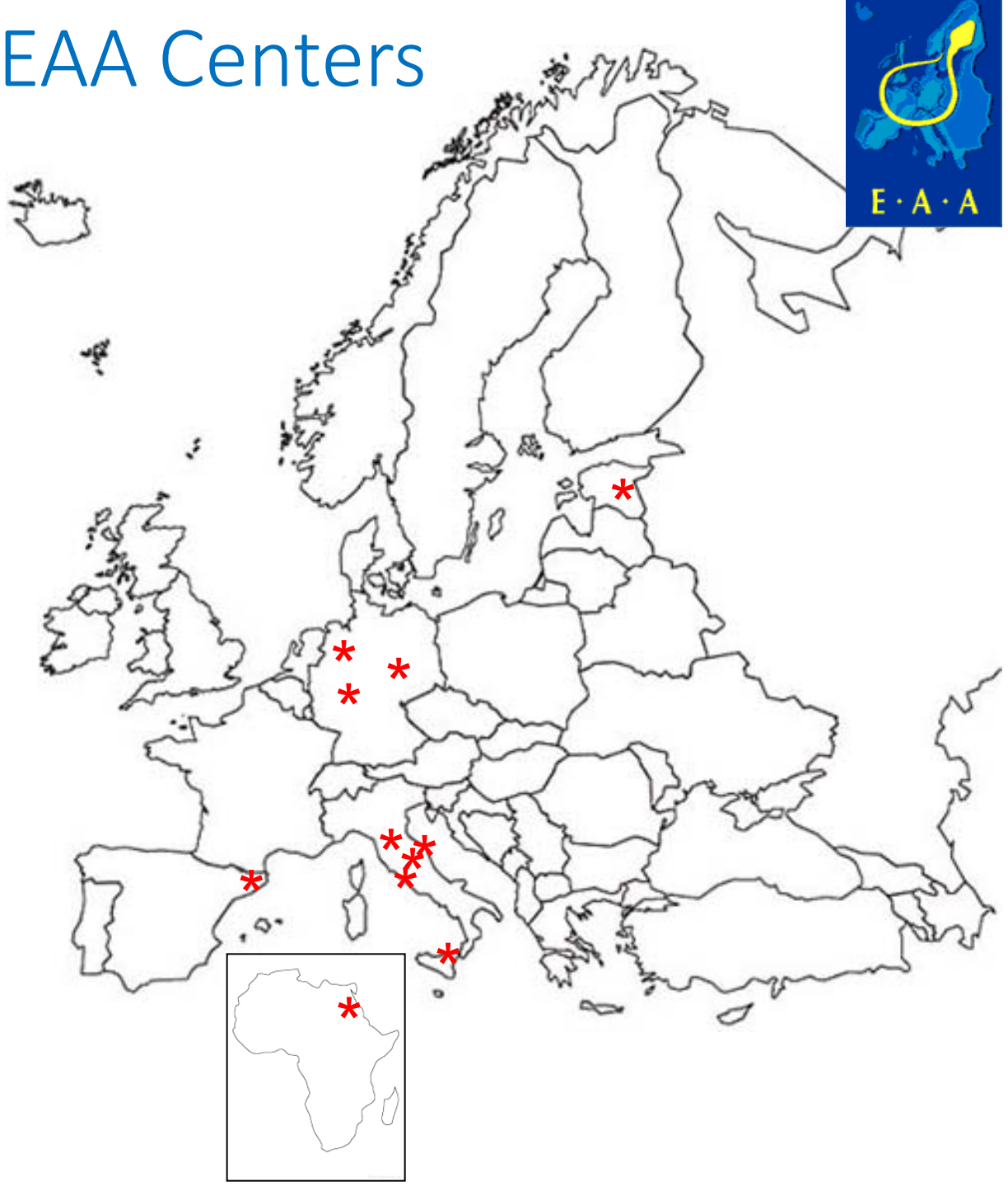

Aim of the study

-Descriptive: to evaluate the color-Doppler ultrasound (CDUS) features of the scrotal and prostate-vesicular regions in healthy, fertile men, to obtain "normative" CDUS parameters in a healthy, fertile population.

-Correlative: to correlate CDUS findings with

- clinical parameters
- seminal parameters
- biochemical parameters*

evaluated during the same CDUS session

-Comparative: "control group" vs.

-infertile men

-men with male genital tract inflammation

-men with malignancy

*(LH, FSH, PRL, TSH, FT3, FT4, PSA, total testosterone, SHBG, glycemia, insulin levels, total cholesterol, HDL, triglycerides, 17βE2)

steroids: gas chromatography/mass spectrometry method

Conclusions

- There is increasing evidence for CDUS in MGT inflammation
- Conventional (old) parameters → chronic/past infections/inflammation
- Dynamic (new) parameters → current infection / inflammation
- Several «cut-off» distinguishing normal and pathologic are lacking
- Several «quantitative» parameters are lacking
- The EAA US study will give a «control group»

Thank you

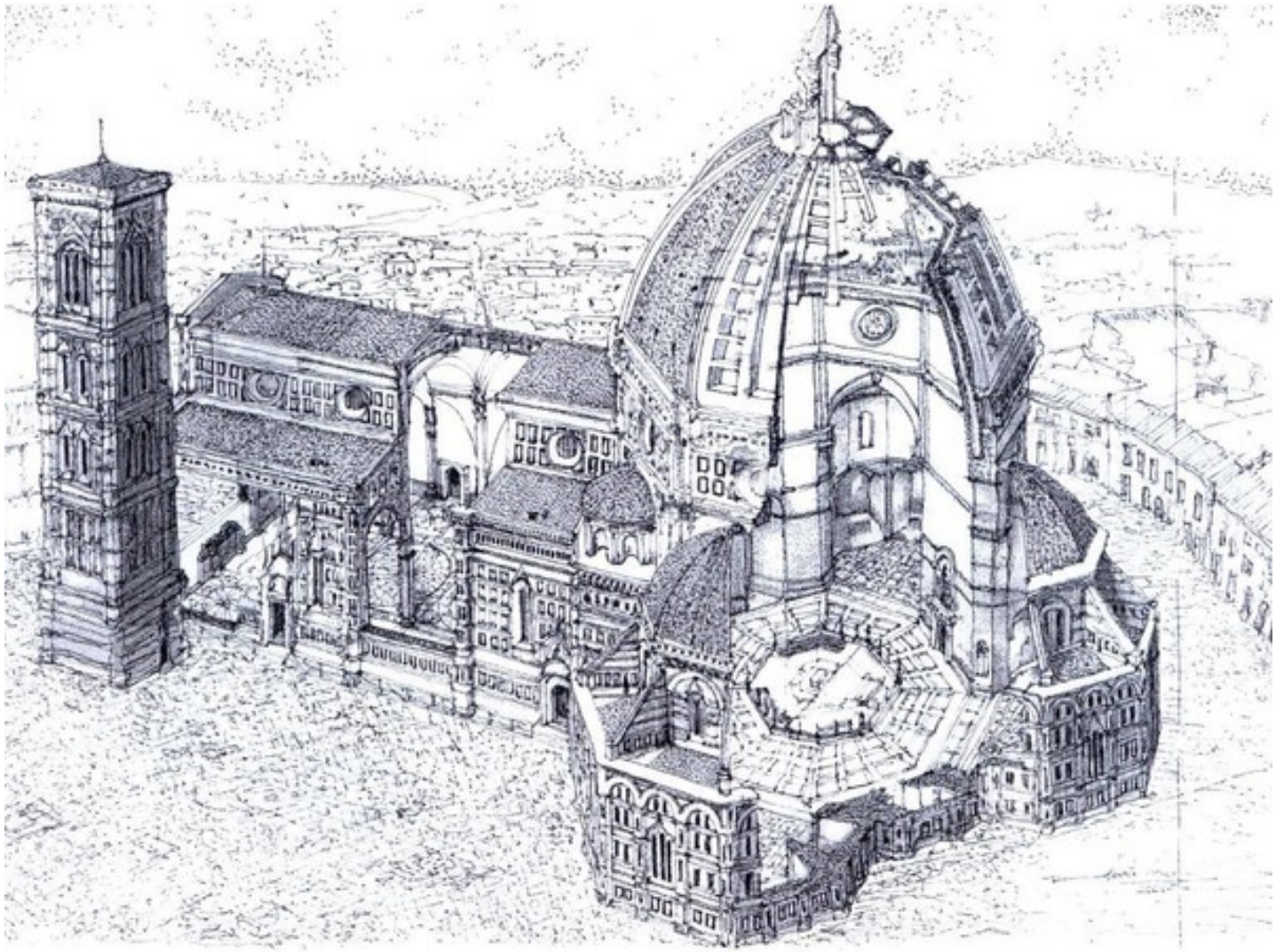

francesco.lotti@unifi.it